

LAPAROSCOPIC (KEYHOLE) REMOVAL OF OVARIAN CYST IN PREGNANCY

MR A K TREHAN, FRCOG, FRCS (Edin)

**CONSULTANT MINIMAL ACCESS GYNAECOLOGIST
WITH SPECIAL INTEREST IN ENDOMETRIOSIS**

**DEWSBURY & DISTRICT HOSPITAL
WEST YORKSHIRE
ENGLAND, UK**

LAPAROSCOPIC (KEYHOLE) REMOVAL OF OVARIAN CYST IN PREGNANCY

**THE TEXT IN PREPARATION MOVE ON TO THE
NEXT SLIDE**

LAPAROSCOPIC (KEYHOLE) REMOVAL OF OVARIAN CYST IN PREGNANCY

- **The next fourteen photographs belong to the same patient. An ovarian cyst was diagnosed at the time of routine ultrasound for pregnancy.**
- **The keyhole operation was undertaken to remove the cyst from the right ovary preserving the healthy right ovarian tissue.**
- **The cyst was successfully shelled off from the normal healthy ovarian tissue. The remains of the healthy ovarian tissue was stitched together to reconstruct the right ovary.**
- **This patient went on to full term of pregnancy and delivered a normal, healthy baby**

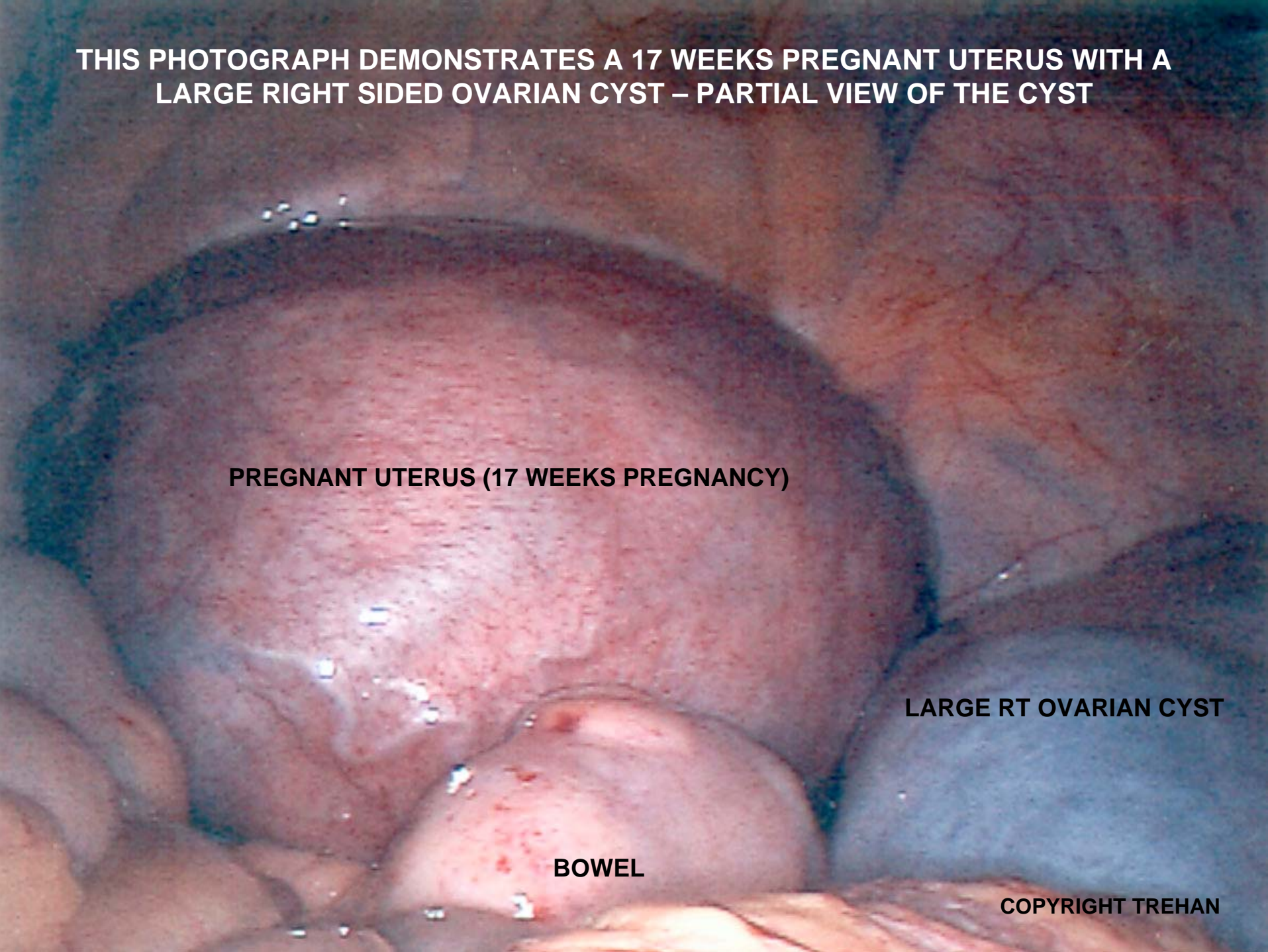
**THIS PHOTOGRAPH DEMONSTRATES A 17 WEEKS PREGNANT UTERUS WITH A
LARGE RIGHT SIDED OVARIAN CYST – PARTIAL VIEW OF THE CYST**

PREGNANT UTERUS (17 WEEKS PREGNANCY)

LARGE RT OVARIAN CYST

BOWEL

COPYRIGHT TREHAN



**THIS PHOTOGRAPH DEMONSTRATES A 17 WEEKS PREGNANT UTERUS WITH A
LARGE RIGHT SIDED OVARIAN CYST – FULL VIEW OF THE CYST**

**PREGNANT UTERUS
(17 WEEKS PREGNANCY)**

LARGE RT OVARIAN CYST

BOWEL

COPYRIGHT TREHAN

THIS PHOTOGRAPH DEMONSTRATES A LARGE RIGHT SIDED OVARIAN CYST – (PARTIAL VIEW OF THE CYST) AND LIVER.

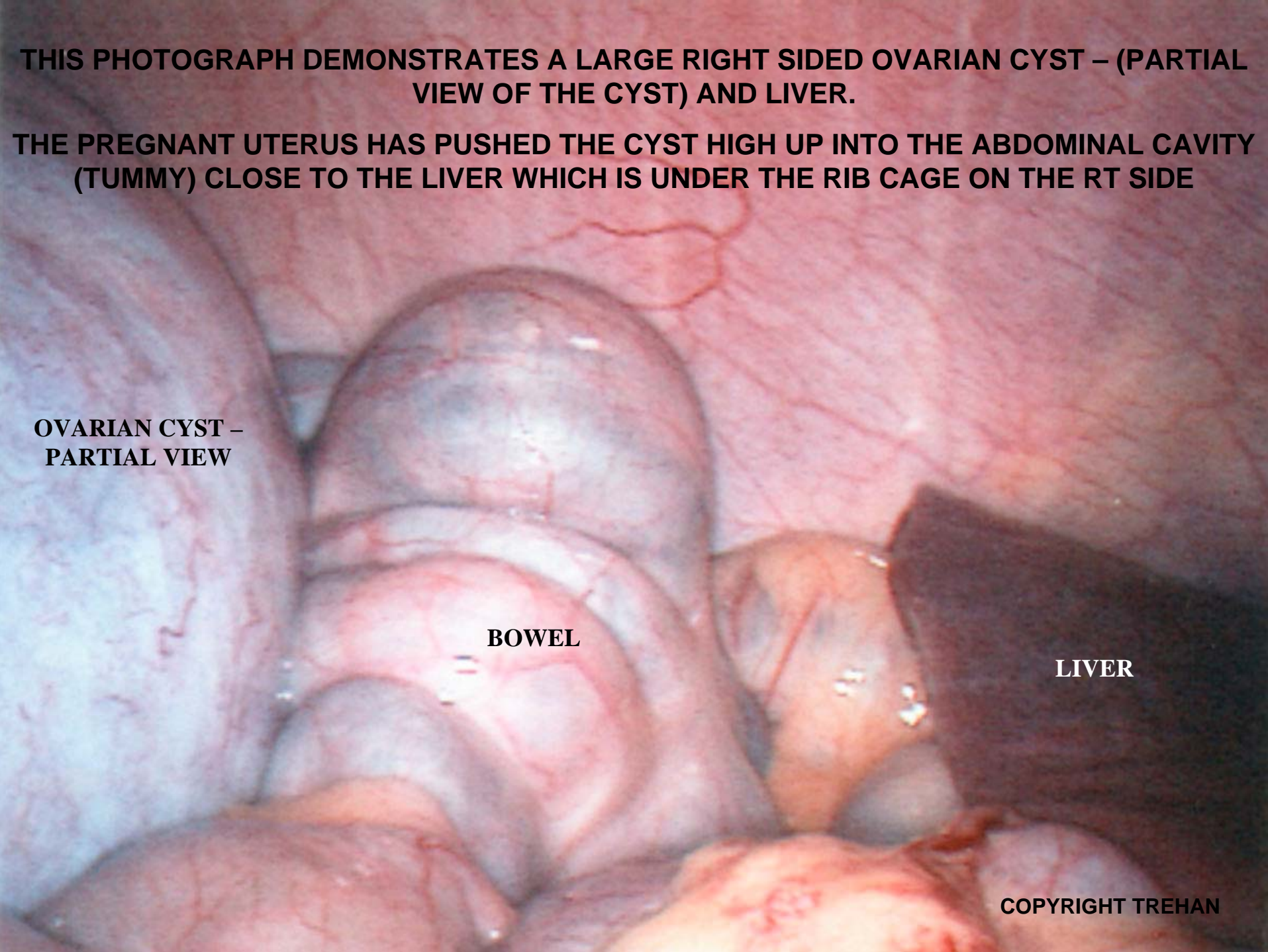
THE PREGNANT UTERUS HAS PUSHED THE CYST HIGH UP INTO THE ABDOMINAL CAVITY (TUMMY) CLOSE TO THE LIVER WHICH IS UNDER THE RIB CAGE ON THE RT SIDE

**OVARIAN CYST –
PARTIAL VIEW**

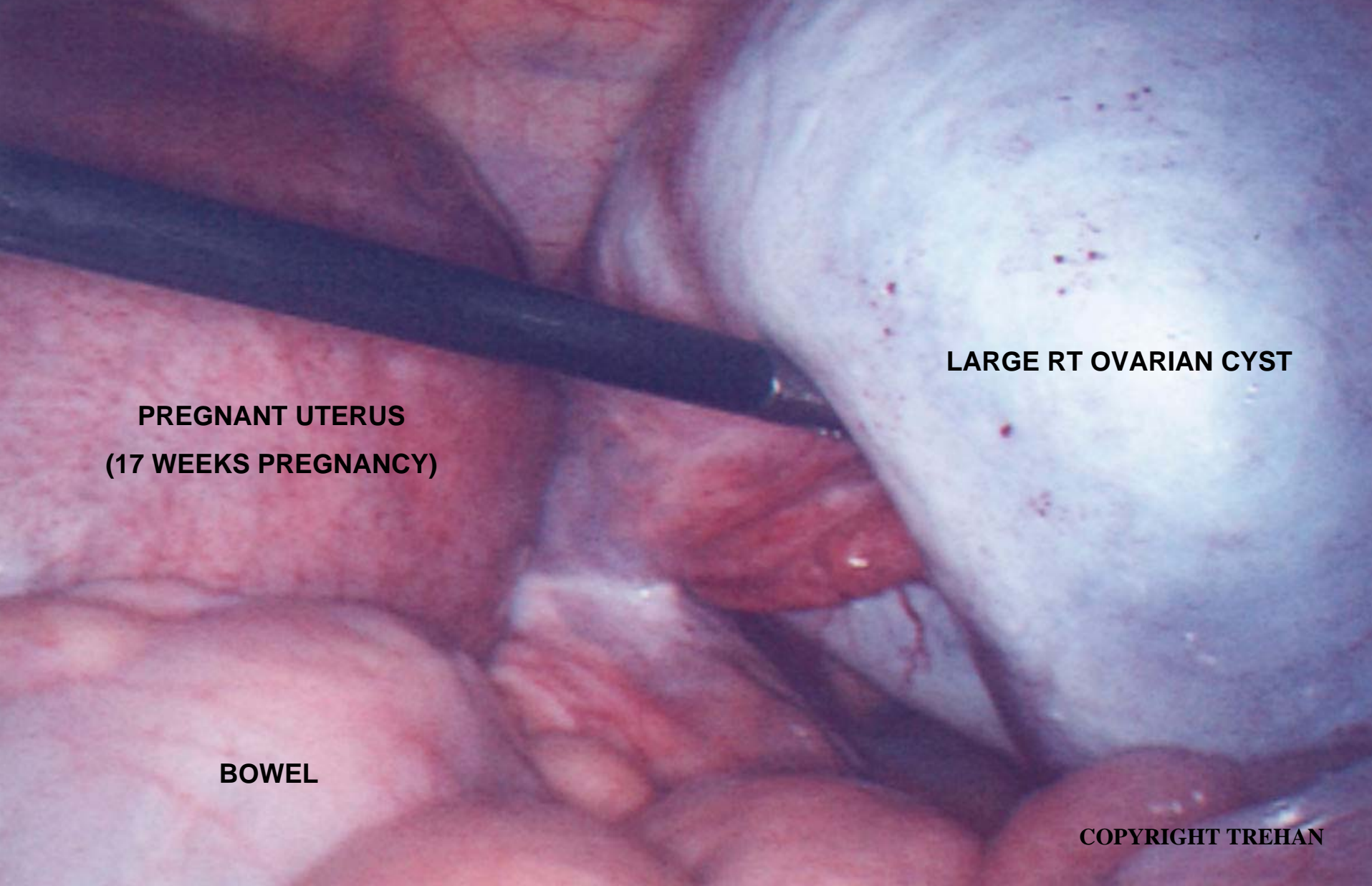
BOWEL

LIVER

COPYRIGHT TREHAN



**THIS PHOTOGRAPH DEMONSTRATES A 17 WEEKS PREGNANT UTERUS WITH A LARGE
RIGHT SIDED OVARIAN CYST – AN INSTRUMENT IS BEING USED TO LIFT THE CYST
(KEYHOLE OPERATION IN PROGRESS)**



LARGE RT OVARIAN CYST

**PREGNANT UTERUS
(17 WEEKS PREGNANCY)**

BOWEL

COPYRIGHT TREHAN

THIS PHOTOGRAPH DEMONSTRATES A 17 WEEKS PREGNANT UTERUS WITH A LARGE RIGHT SIDED OVARIAN CYST – A NEEDLE IS BEING USED TO DEFLATE THE CYST BY REMOVING THE FLUID WITHIN THE CYST (KEYHOLE OPERATION IN PROGRESS)

A LARGE BORE NEEDLE HAS BEEN INSERTED INTO THE CYST TO REMOVE THE FLUID FROM THE CYST



**PREGNANT UTERUS
(17 WEEKS PREGNANCY)**

LARGE RT OVARIAN CYST

THIS PHOTOGRAPH DEMONSTRATES A 17 WEEKS PREGNANT UTERUS WITH A DEFLATED RIGHT SIDED OVARIAN CYST AFTER REMOVAL OF THE FLUID FROM THE OVARIAN CYST WITH THE HELP OF A LARGE BORE NEEDLE (KEYHOLE OPERATION IN PROGRESS)

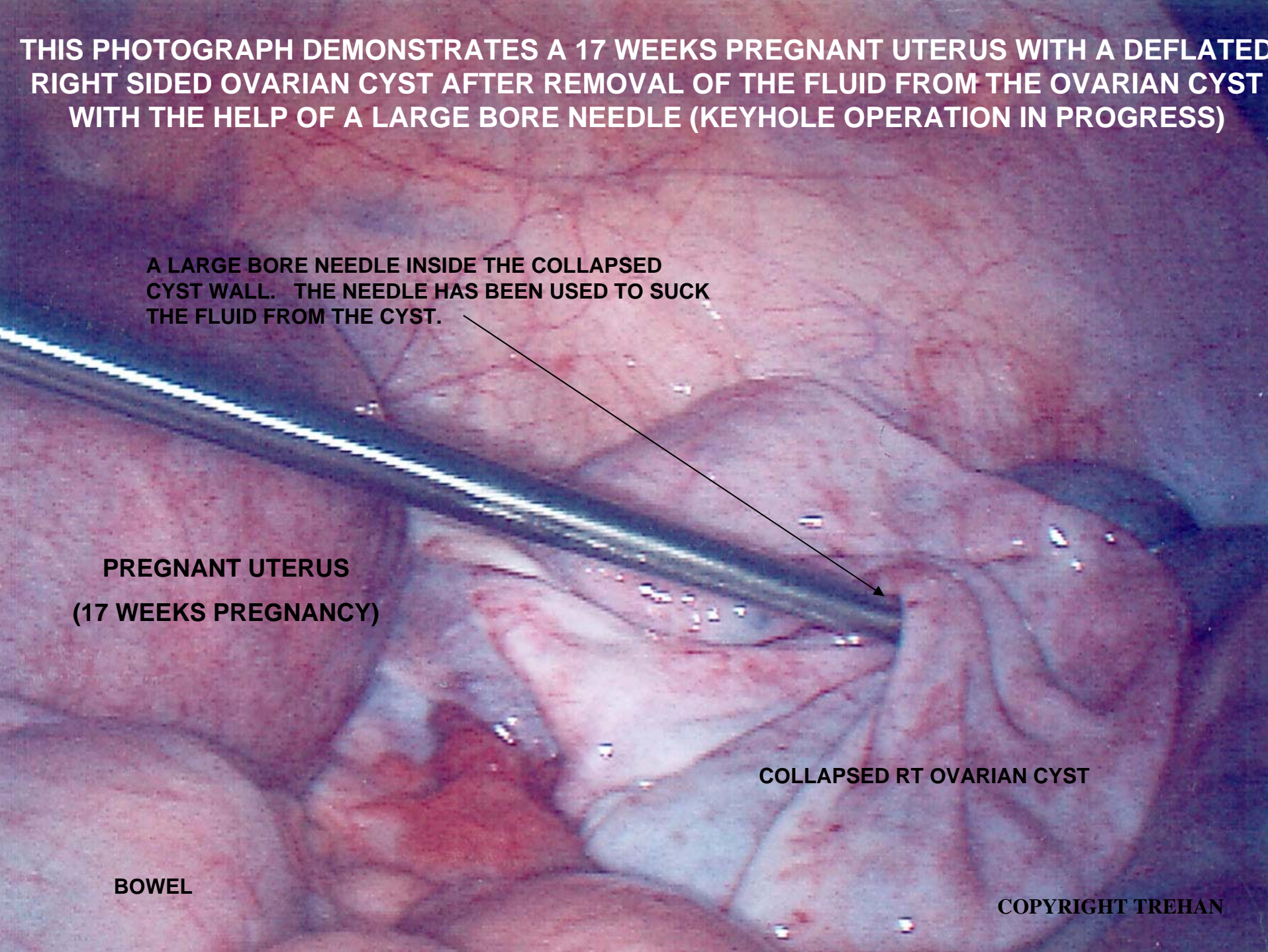
A LARGE BORE NEEDLE INSIDE THE COLLAPSED CYST WALL. THE NEEDLE HAS BEEN USED TO SUCK THE FLUID FROM THE CYST.

**PREGNANT UTERUS
(17 WEEKS PREGNANCY)**

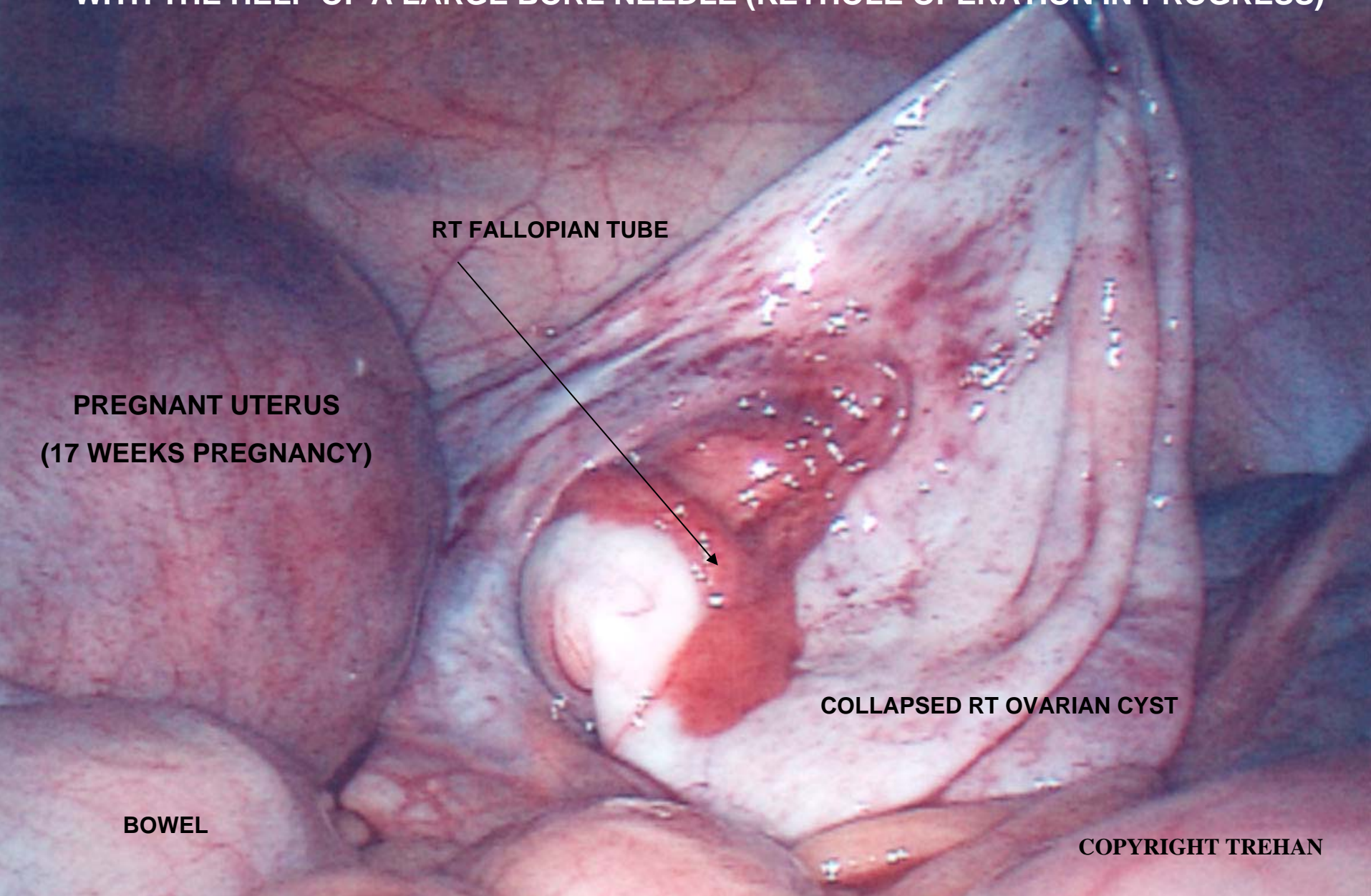
COLLAPSED RT OVARIAN CYST

BOWEL

COPYRIGHT TREHAN



THIS PHOTOGRAPH DEMONSTRATES A 17 WEEKS PREGNANT UTERUS WITH A DEFLATED RIGHT SIDED OVARIAN CYST AFTER REMOVAL OF THE FLUID FROM THE OVARIAN CYST WITH THE HELP OF A LARGE BORE NEEDLE (KEYHOLE OPERATION IN PROGRESS)



RT FALLOPIAN TUBE

**PREGNANT UTERUS
(17 WEEKS PREGNANCY)**

COLLAPSED RT OVARIAN CYST

BOWEL

COPYRIGHT TREHAN

THIS PHOTOGRAPH DEMONSTRATES A 17 WEEKS PREGNANT UTERUS WITH A DEFLATED RIGHT SIDED OVARIAN CYST. THE CYST IS BEING REMOVED FROM NORMAL OVARIAN TISSUE (KEYHOLE OPERATION IN PROGRESS)

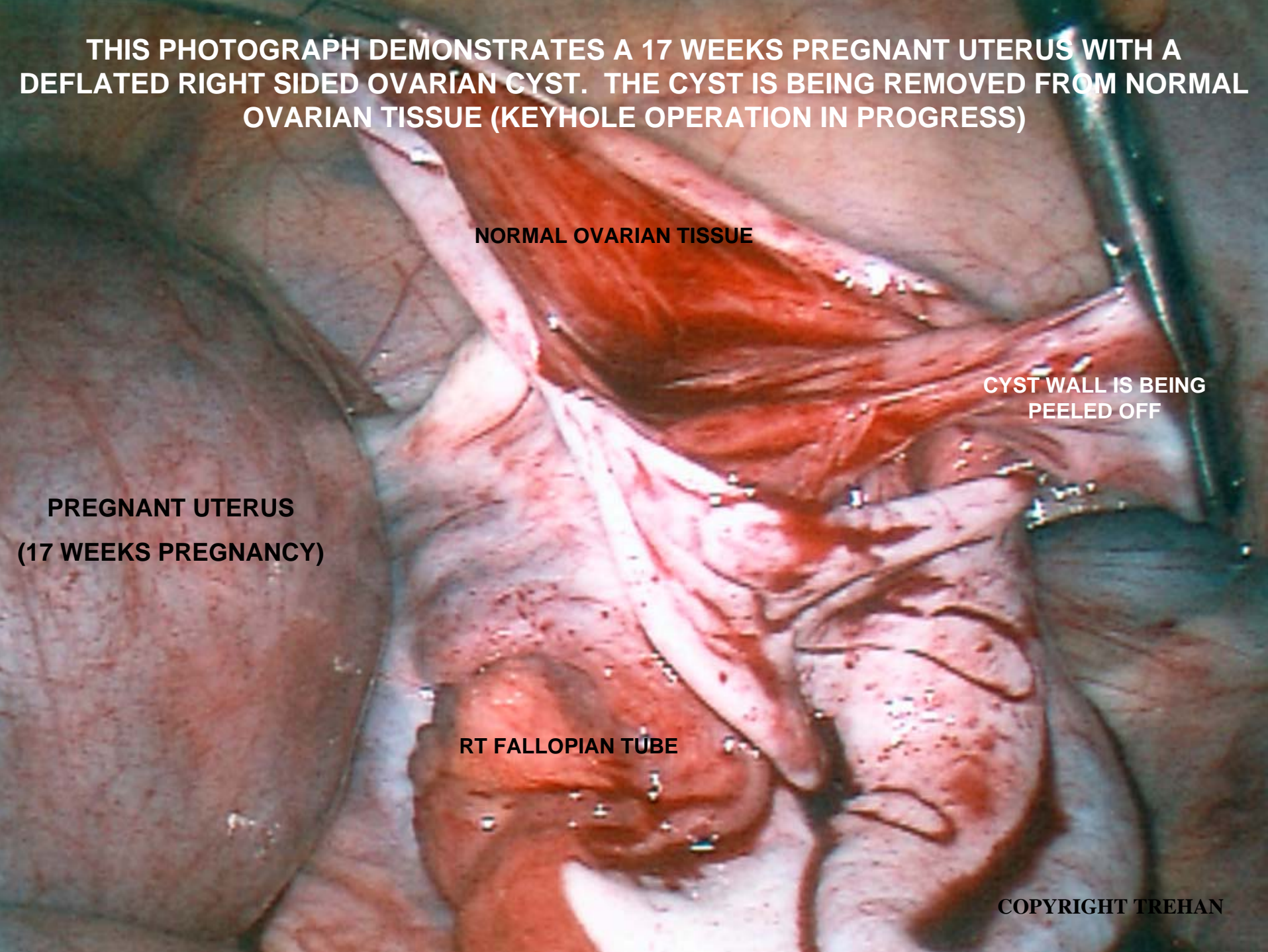
NORMAL OVARIAN TISSUE

**CYST WALL IS BEING
PEELED OFF**

**PREGNANT UTERUS
(17 WEEKS PREGNANCY)**

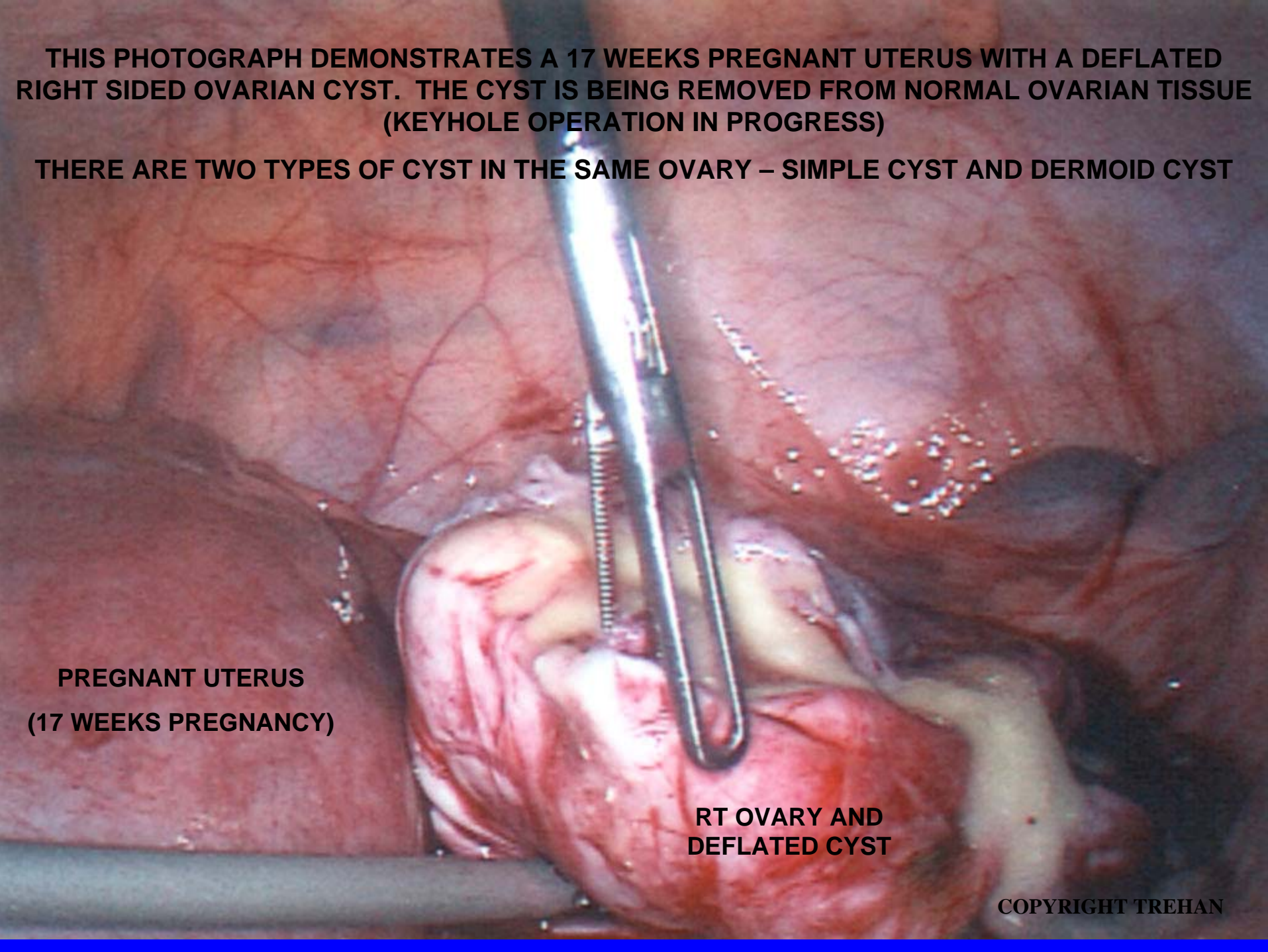
RT FALLOPIAN TUBE

COPYRIGHT TREHAN



THIS PHOTOGRAPH DEMONSTRATES A 17 WEEKS PREGNANT UTERUS WITH A DEFLATED RIGHT SIDED OVARIAN CYST. THE CYST IS BEING REMOVED FROM NORMAL OVARIAN TISSUE (KEYHOLE OPERATION IN PROGRESS)

THERE ARE TWO TYPES OF CYST IN THE SAME OVARY – SIMPLE CYST AND DERMOID CYST

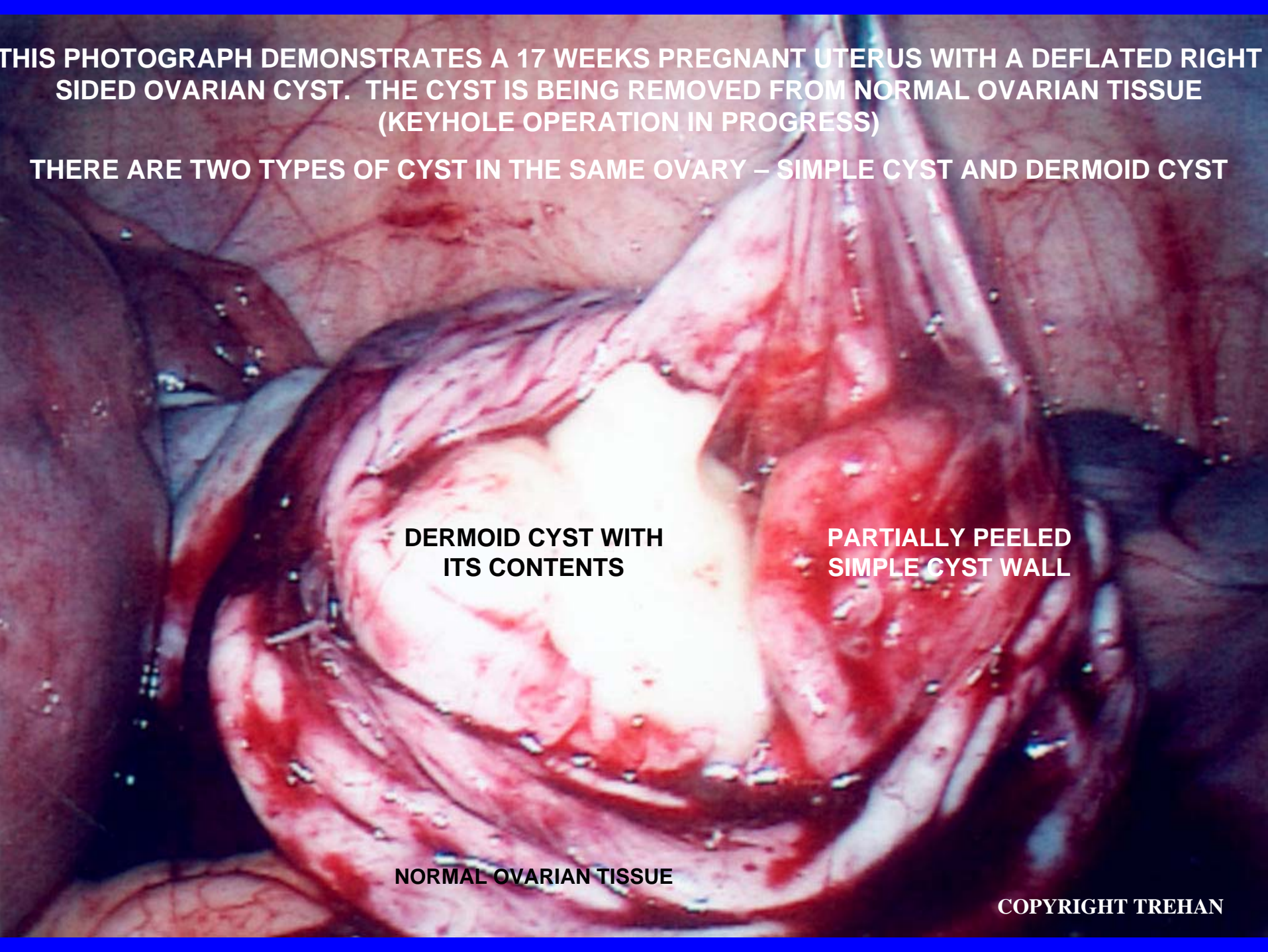


**PREGNANT UTERUS
(17 WEEKS PREGNANCY)**

**RT OVARY AND
DEFLATED CYST**

THIS PHOTOGRAPH DEMONSTRATES A 17 WEEKS PREGNANT UTERUS WITH A DEFLATED RIGHT SIDED OVARIAN CYST. THE CYST IS BEING REMOVED FROM NORMAL OVARIAN TISSUE (KEYHOLE OPERATION IN PROGRESS)

THERE ARE TWO TYPES OF CYST IN THE SAME OVARY – SIMPLE CYST AND DERMOID CYST

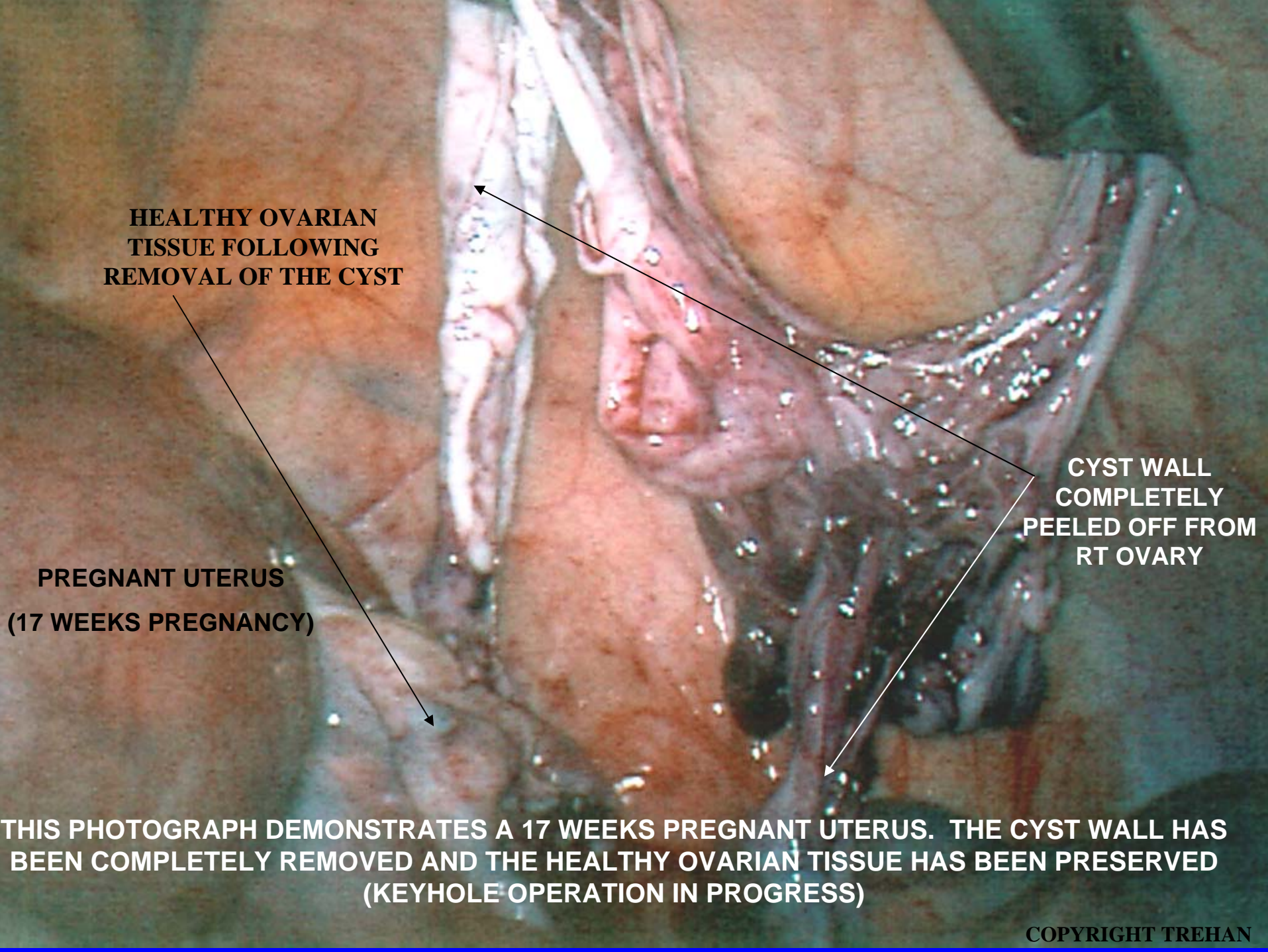


**DERMOID CYST WITH
ITS CONTENTS**

**PARTIALLY PEELED
SIMPLE CYST WALL**

NORMAL OVARIAN TISSUE

COPYRIGHT TREHAN

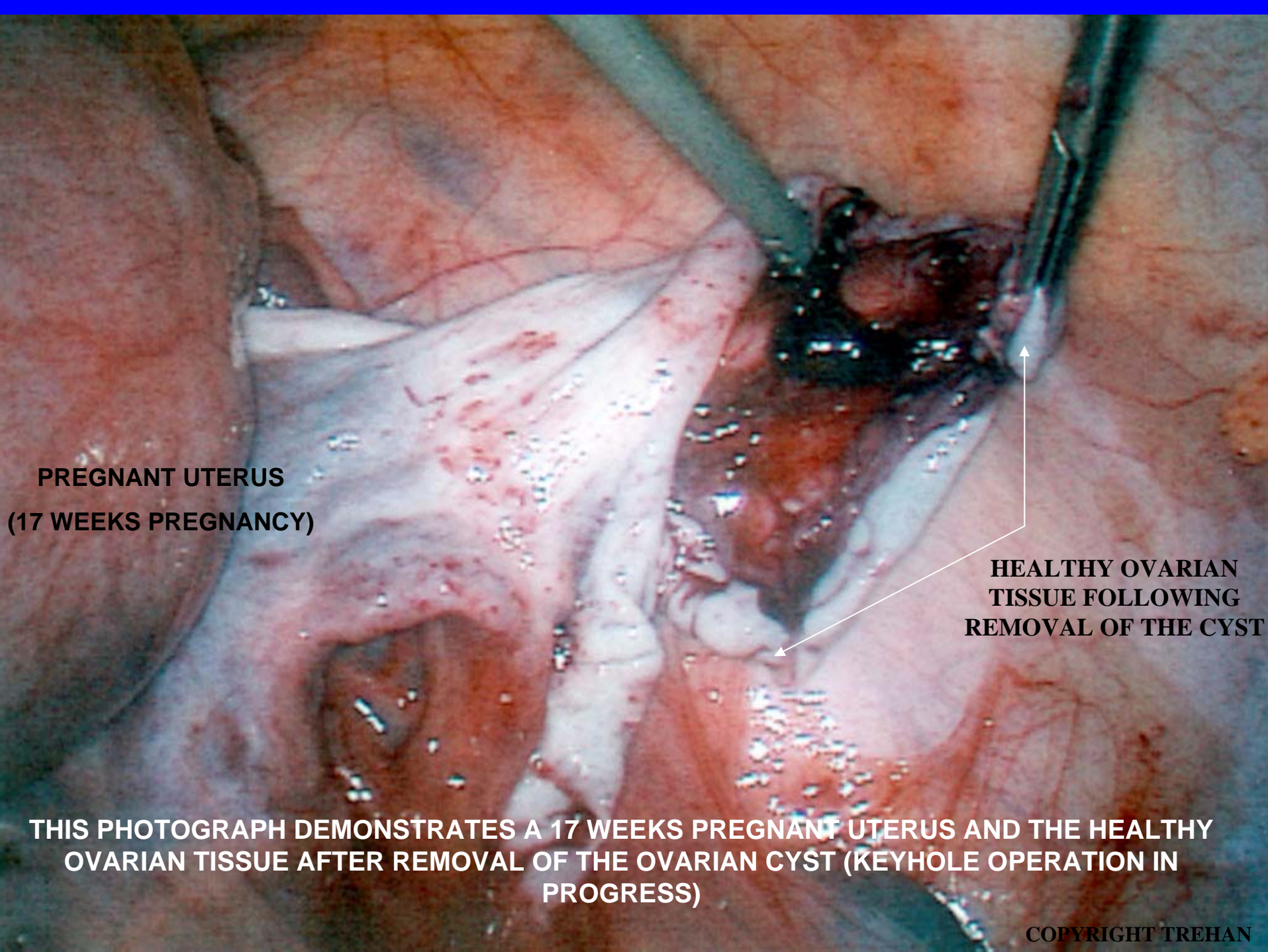


**HEALTHY OVARIAN
TISSUE FOLLOWING
REMOVAL OF THE CYST**

**PREGNANT UTERUS
(17 WEEKS PREGNANCY)**

**CYST WALL
COMPLETELY
PEELED OFF FROM
RT OVARY**

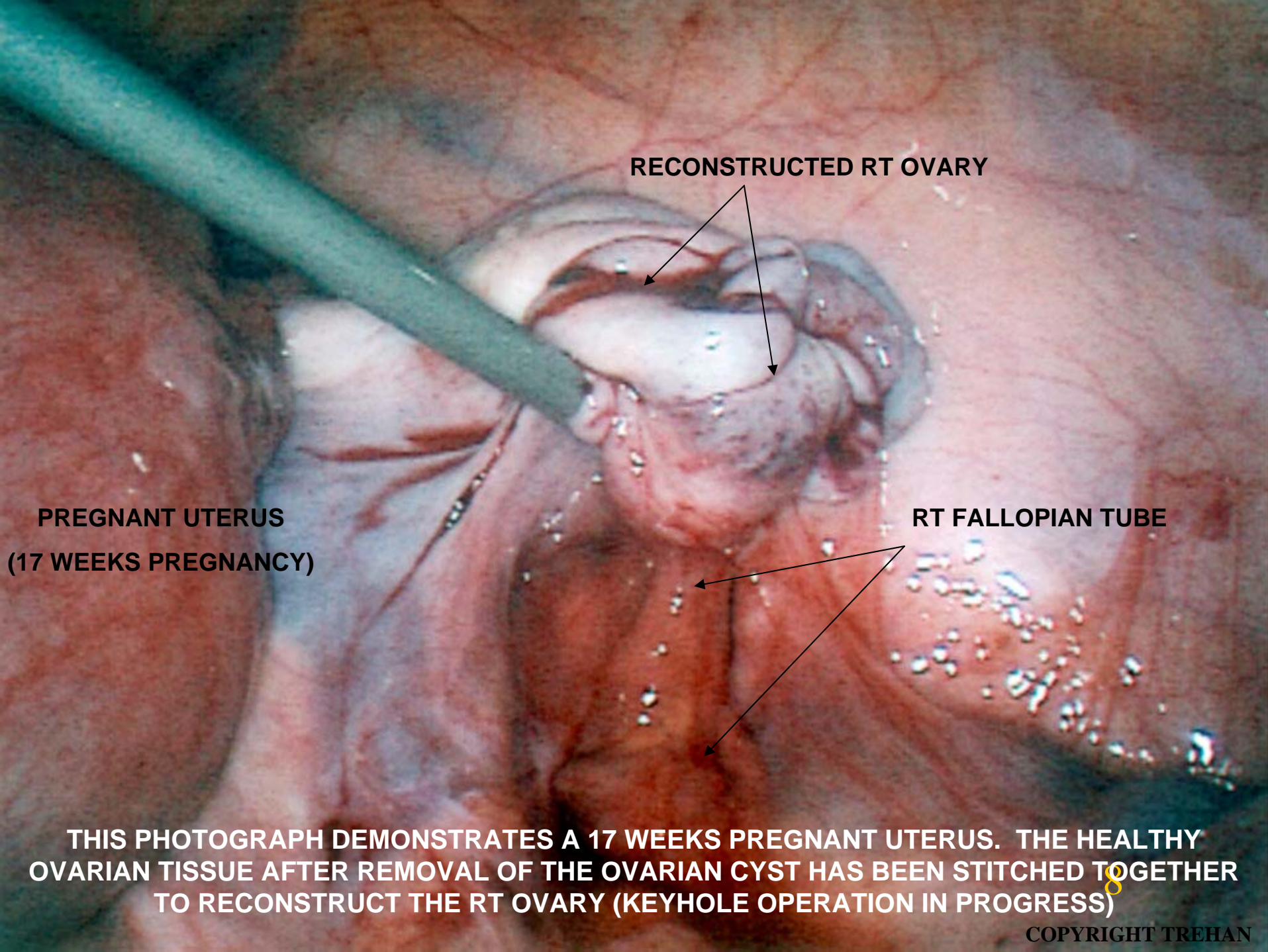
**THIS PHOTOGRAPH DEMONSTRATES A 17 WEEKS PREGNANT UTERUS. THE CYST WALL HAS
BEEN COMPLETELY REMOVED AND THE HEALTHY OVARIAN TISSUE HAS BEEN PRESERVED
(KEYHOLE OPERATION IN PROGRESS)**



**PREGNANT UTERUS
(17 WEEKS PREGNANCY)**

**HEALTHY OVARIAN
TISSUE FOLLOWING
REMOVAL OF THE CYST**

**THIS PHOTOGRAPH DEMONSTRATES A 17 WEEKS PREGNANT UTERUS AND THE HEALTHY
OVARIAN TISSUE AFTER REMOVAL OF THE OVARIAN CYST (KEYHOLE OPERATION IN
PROGRESS)**



RECONSTRUCTED RT OVARY

**PREGNANT UTERUS
(17 WEEKS PREGNANCY)**

RT FALLOPIAN TUBE

THIS PHOTOGRAPH DEMONSTRATES A 17 WEEKS PREGNANT UTERUS. THE HEALTHY OVARIAN TISSUE AFTER REMOVAL OF THE OVARIAN CYST HAS BEEN STITCHED TOGETHER TO RECONSTRUCT THE RT OVARY (KEYHOLE OPERATION IN PROGRESS)

THIS PHOTOGRAPH DEMONSTRATES A 17 WEEKS PREGNANT UTERUS AND RECONSTRUCTED RT OVARY. THE OVARIAN CYST HAS BEEN COMPLETELY REMOVED SUCCESSFULLY (END OF KEYHOLE OPERATION)

**PREGNANT UTERUS
(17 WEEKS PREGNANCY)**



**THIS PATIENT WENT ON TO FULL
TERM OF PREGNANCY AND
DELIVERED A HEALTHY BABY**

RECONSTRUCTED RT OVARY

**SPECIAL FLUID LEFT TO
PREVENT ADHESIONS**

BOWEL