

LAPAROSCOPIC (KEYHOLE) MANAGEMENT OF ECTOPIC PREGNANCY

MR A K TREHAN, FRCOG, FRCS (Edin)

**CONSULTANT MINIMAL ACCESS
GYNAECOLOGIST
WITH SPECIAL INTEREST IN
ENDOMETRIOSIS**

**DEWSBURY & DISTRICT HOSPITAL
WEST YORKSHIRE
ENGLAND, UK**

LAPAROSCOPIC (KEYHOLE) MANAGEMENT OF ECTOPIC PREGNANCY

**THE TEXT IN PREPARATION MOVE ON
TO THE NEXT SLIDE**

LAPAROSCOPIC (KEYHOLE) MANAGEMENT OF UNRUPTURED ECTOPIC PREGNANCY IN FALLOPIAN TUBE

- The next eight photographs belong to the same patient who has pregnancy in the left fallopian tube (ectopic pregnancy) instead of in the uterus.
- The left fallopian tube with ectopic is intact and has not given way (ruptured) as the ectopic pregnancy has been diagnosed early.
- There is no active bleeding as the left fallopian tube is intact and has not given way (ruptured).
- The keyhole operation is undertaken to remove the ectopic pregnancy from inside the left fallopian tube leaving the fallopian tube intact.
- The photographs demonstrate the technique of removing the ectopic pregnancy from the left fallopian tube and then cleaning and washing the inside of the fallopian tube with saline solution.
- This technique allows preservation of the fallopian tube with the hope that it might work in the future although there is always a risk of future ectopic pregnancy.

THIS PHOTOGRAPH DEMONSTRATES PREGNANCY IN THE LEFT FALLOPIAN TUBE THE DIAGNOSIS HAS BEEN MADE EARLY AND SO THE FALLOPIAN TUBE IS INTACT AND THERE IS NO OBVIOUS BLEEDING.

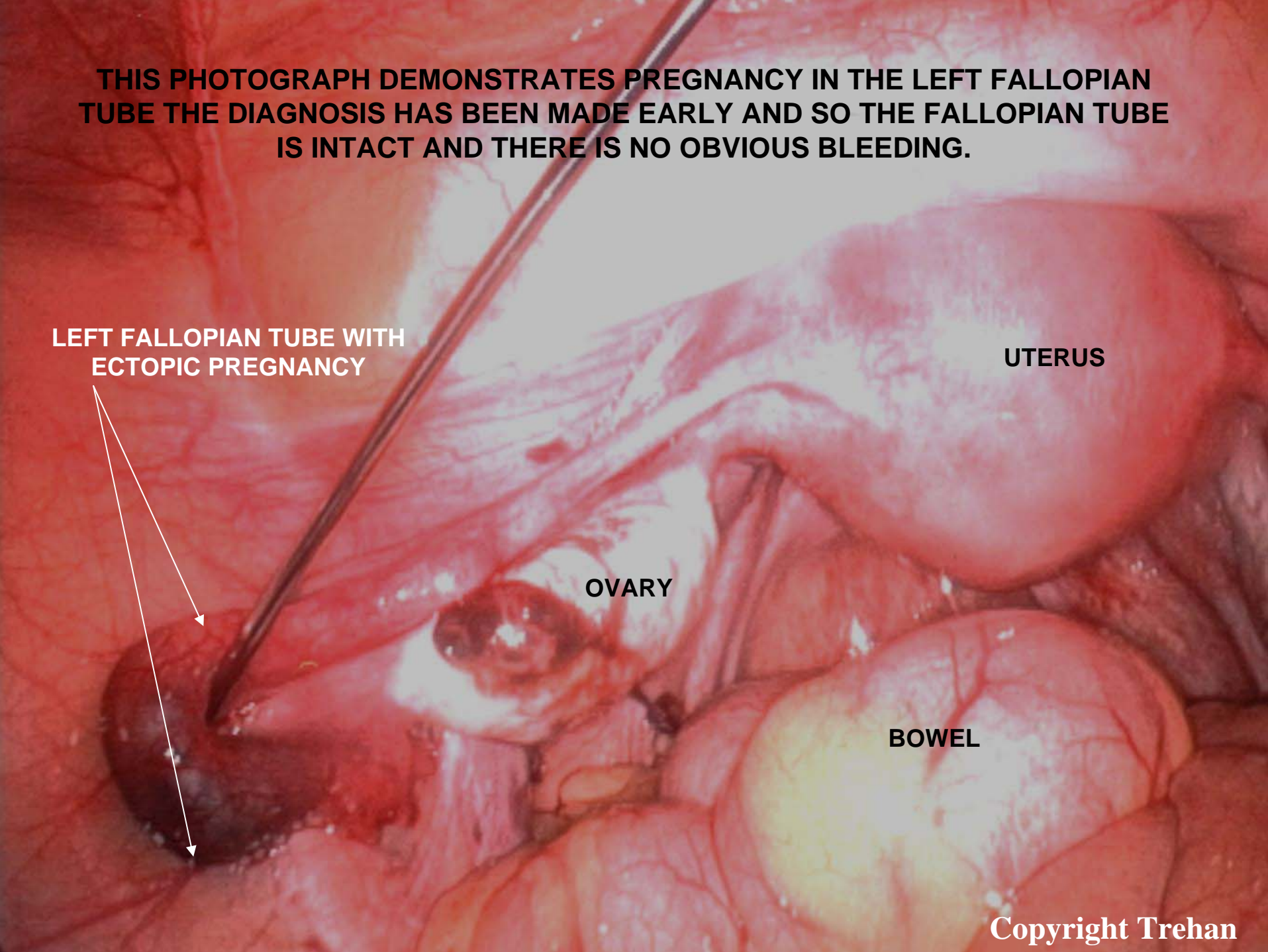
**LEFT FALLOPIAN TUBE WITH
ECTOPIC PREGNANCY**

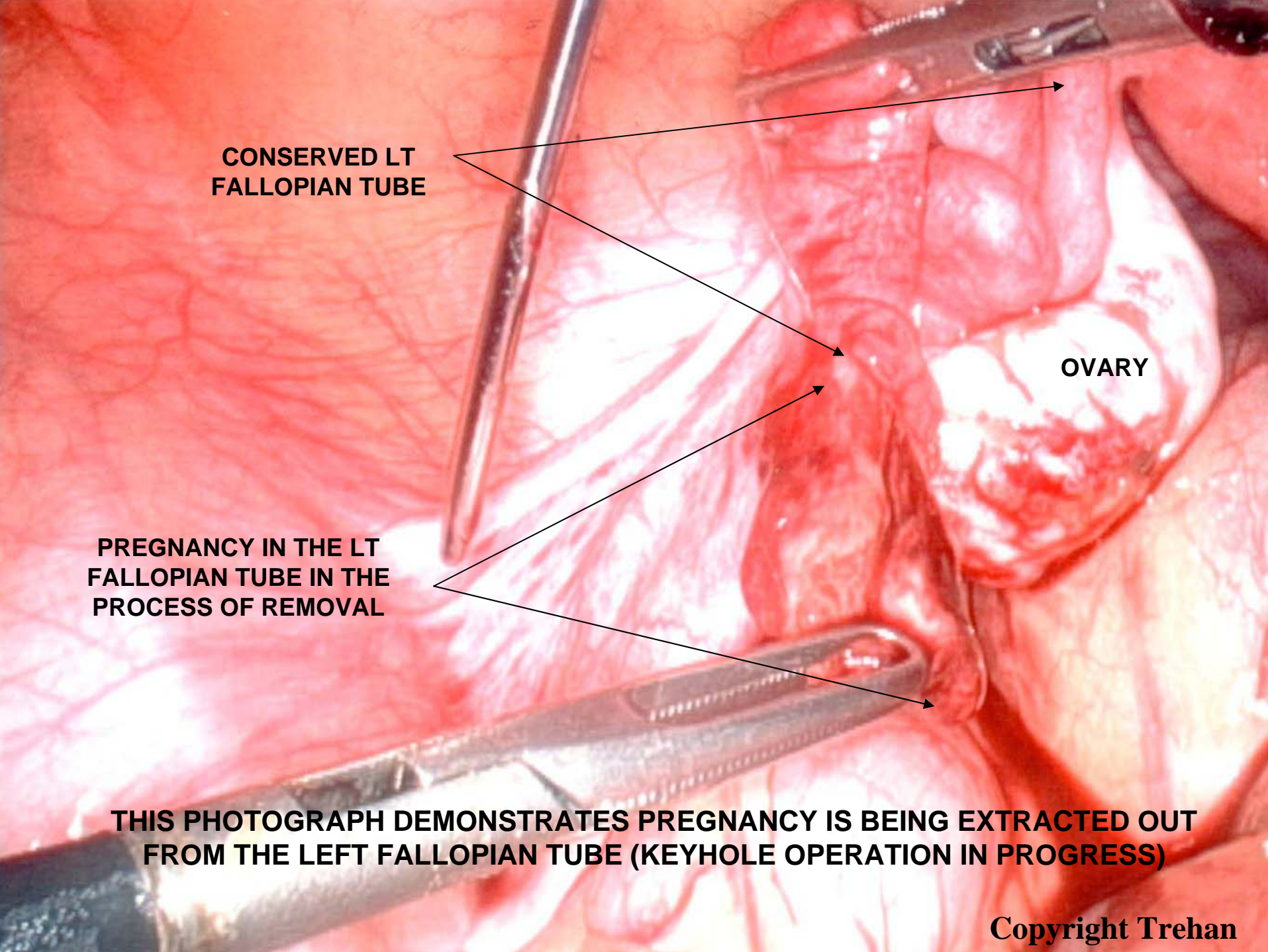
UTERUS

OVARY

BOWEL

Copyright Trehan





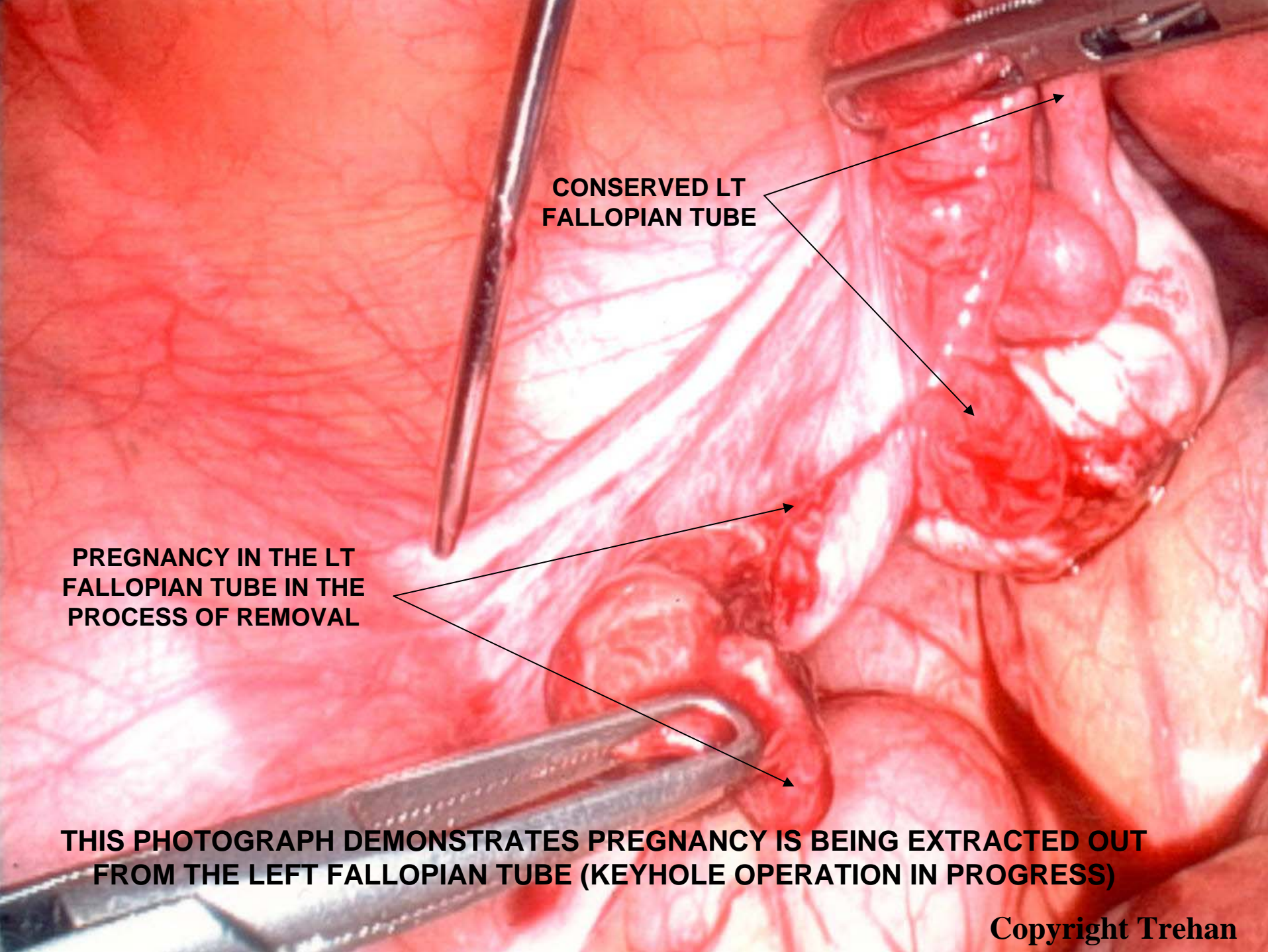
**CONSERVED LT
FALLOPIAN TUBE**

OVARY

**PREGNANCY IN THE LT
FALLOPIAN TUBE IN THE
PROCESS OF REMOVAL**

**THIS PHOTOGRAPH DEMONSTRATES PREGNANCY IS BEING EXTRACTED OUT
FROM THE LEFT FALLOPIAN TUBE (KEYHOLE OPERATION IN PROGRESS)**

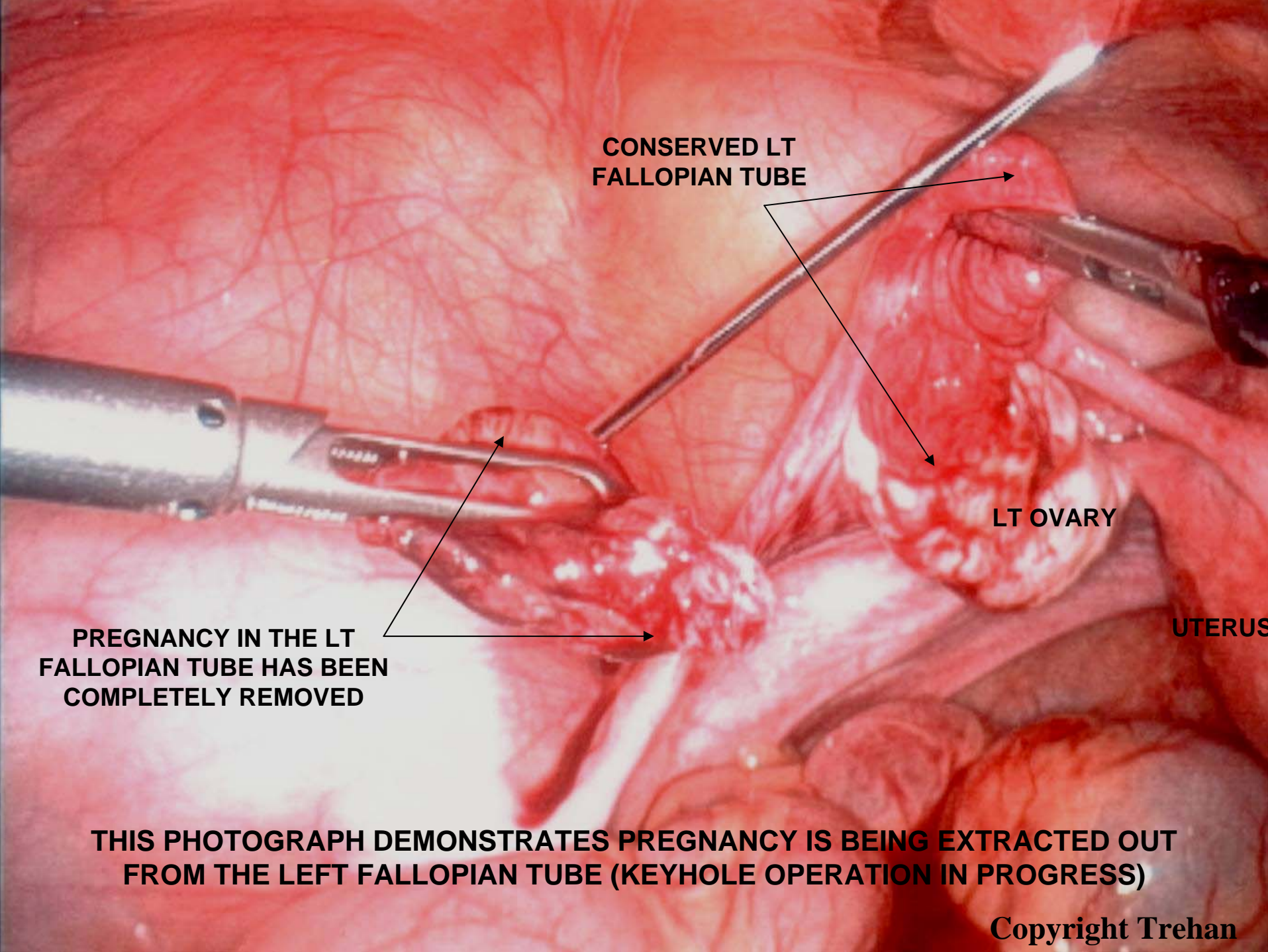
Copyright Trehan



**CONSERVED LT
FALLOPIAN TUBE**

**PREGNANCY IN THE LT
FALLOPIAN TUBE IN THE
PROCESS OF REMOVAL**

**THIS PHOTOGRAPH DEMONSTRATES PREGNANCY IS BEING EXTRACTED OUT
FROM THE LEFT FALLOPIAN TUBE (KEYHOLE OPERATION IN PROGRESS)**



**CONSERVED LT
FALLOPIAN TUBE**

LT OVARY

UTERUS

**PREGNANCY IN THE LT
FALLOPIAN TUBE HAS BEEN
COMPLETELY REMOVED**

**THIS PHOTOGRAPH DEMONSTRATES PREGNANCY IS BEING EXTRACTED OUT
FROM THE LEFT FALLOPIAN TUBE (KEYHOLE OPERATION IN PROGRESS)**

Copyright Trehan

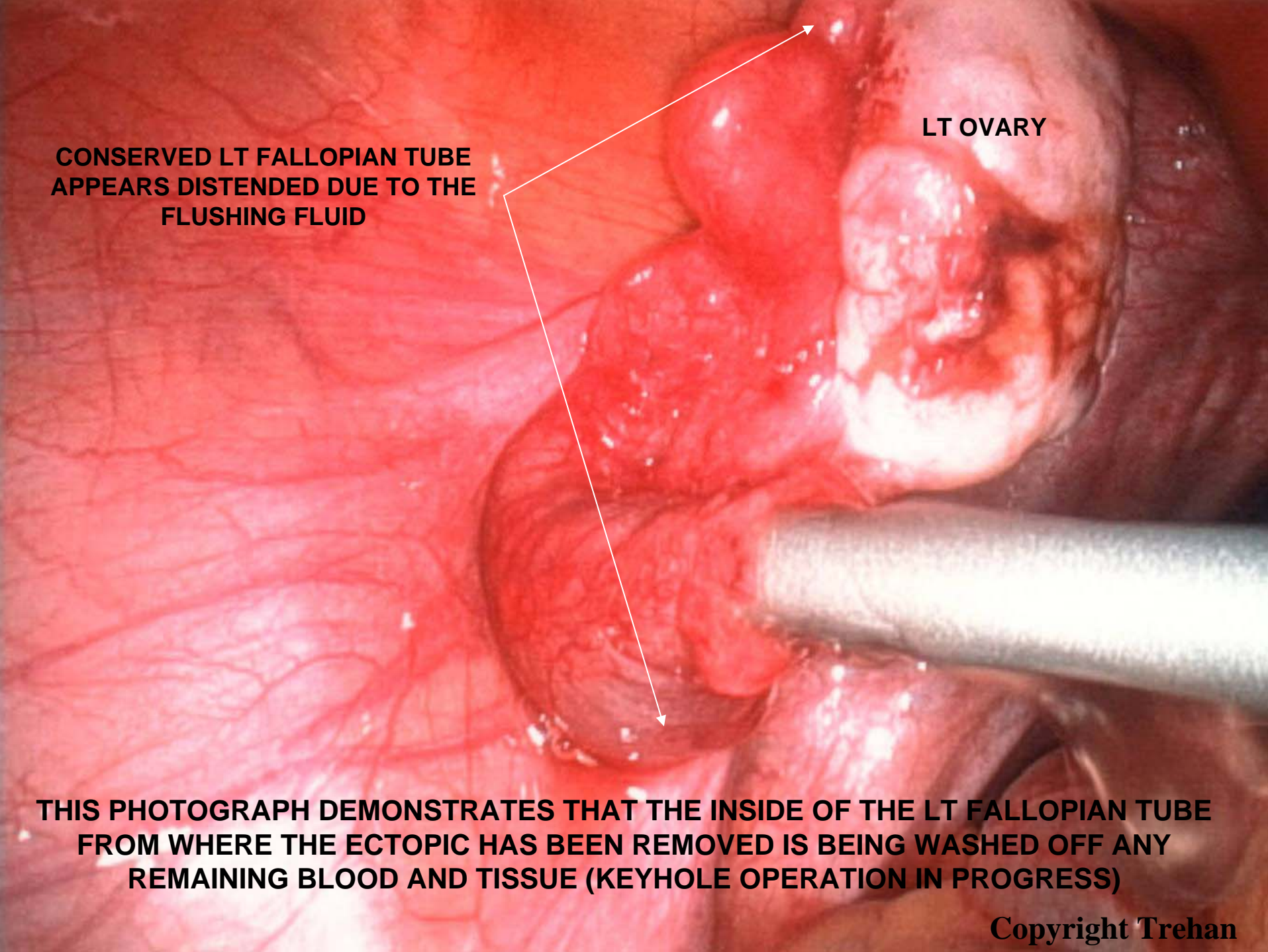
**CONSERVED LT FALLOPIAN TUBE
APPEARS DISTENDED DUE TO THE
FLUSHING FLUID**

LT OVARY

UTERUS

**THIS PHOTOGRAPH DEMONSTRATES THAT THE INSIDE OF THE LT FALLOPIAN TUBE
FROM WHERE THE ECTOPIC HAS BEEN REMOVED IS BEING WASHED OFF ANY
REMAINING BLOOD AND TISSUE (KEYHOLE OPERATION IN PROGRESS)**

Copyright Trehan



**CONSERVED LT FALLOPIAN TUBE
APPEARS DISTENDED DUE TO THE
FLUSHING FLUID**

LT OVARY

**THIS PHOTOGRAPH DEMONSTRATES THAT THE INSIDE OF THE LT FALLOPIAN TUBE
FROM WHERE THE ECTOPIC HAS BEEN REMOVED IS BEING WASHED OFF ANY
REMAINING BLOOD AND TISSUE (KEYHOLE OPERATION IN PROGRESS)**

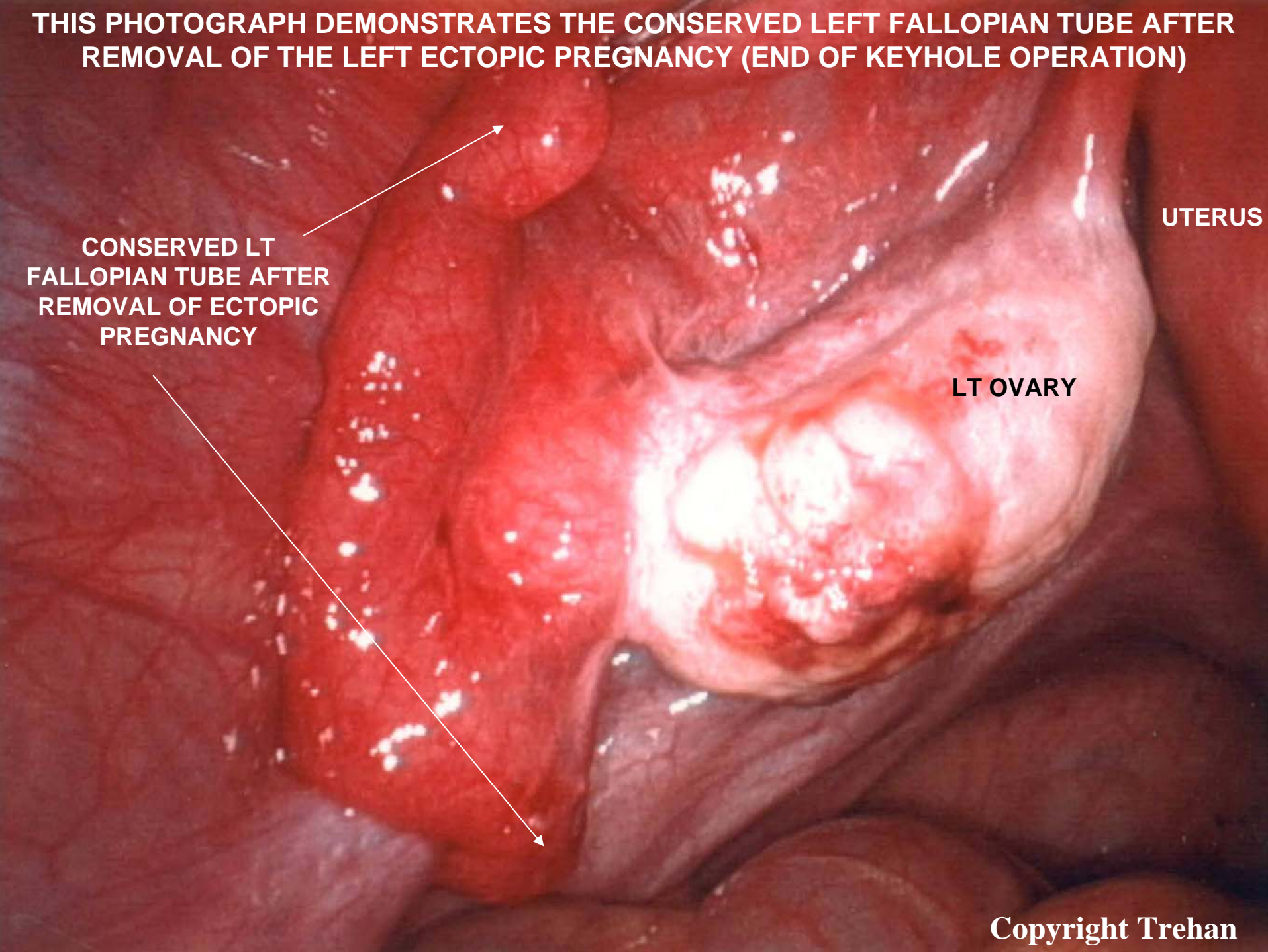
THIS PHOTOGRAPH DEMONSTRATES THE CONSERVED LEFT FALLOPIAN TUBE AFTER REMOVAL OF THE LEFT ECTOPIC PREGNANCY (END OF KEYHOLE OPERATION)

**CONSERVED LT
FALLOPIAN TUBE AFTER
REMOVAL OF ECTOPIC
PREGNANCY**

UTERUS

LT OVARY

Copyright Trehan



**CONSERVED LT FALLOPIAN
TUBE AFTER REMOVAL OF
ECTOPIC PREGNANCY**

NORMAL RT FALLOPIAN TUBE

UTERUS

LT OVARY

RT OVARY

THIS PHOTOGRAPH DEMONSTRATES THE PELVIS AT THE END OF THE KEYHOLE OPERATION THE LT FALLOPIAN TUBE FROM WHERE THE ECTOPIC HAS BEEN REMOVED IS GIVING SIMILAR APPEARANCE TO THE RT FALLOPIAN TUBE WHICH WAS NORMAL.

Copyright Trehan

LAPAROSCOPIC (KEYHOLE) MANAGEMENT OF RUPTURED ECTOPIC PREGNANCY IN FALLOPIAN TUBE

- The next four photographs belong to the same patient who has pregnancy in the left fallopian tube (ectopic pregnancy) instead of in the uterus.
- The left fallopian tube with ectopic has given way (ruptured) resulting in active bleeding.
- The keyhole operation is undertaken to remove the ectopic pregnancy along with the ruptured left fallopian tube
- The photographs demonstrate the keyhole technique of removing the ectopic pregnancy along with the ruptured left fallopian tube. The pelvic cavity is washed with saline solution and cleaned of all the blood
- When the fallopian tube is ruptured it cannot be repaired and it needs to come out. The remaining left over part of the fallopian tube will be non functional. It is hoped that the other normal fallopian tube (in this case the right fallopian tube) would be functional for future pregnancy.
- There is always a higher risk of future ectopic pregnancy.

PREGNANCY IN THE LEFT FALLOPIAN TUBE HAS BURST OPEN RESULTING IN BLEEDING WHICH IS EVIDENT IN THIS PHOTOGRAPH.

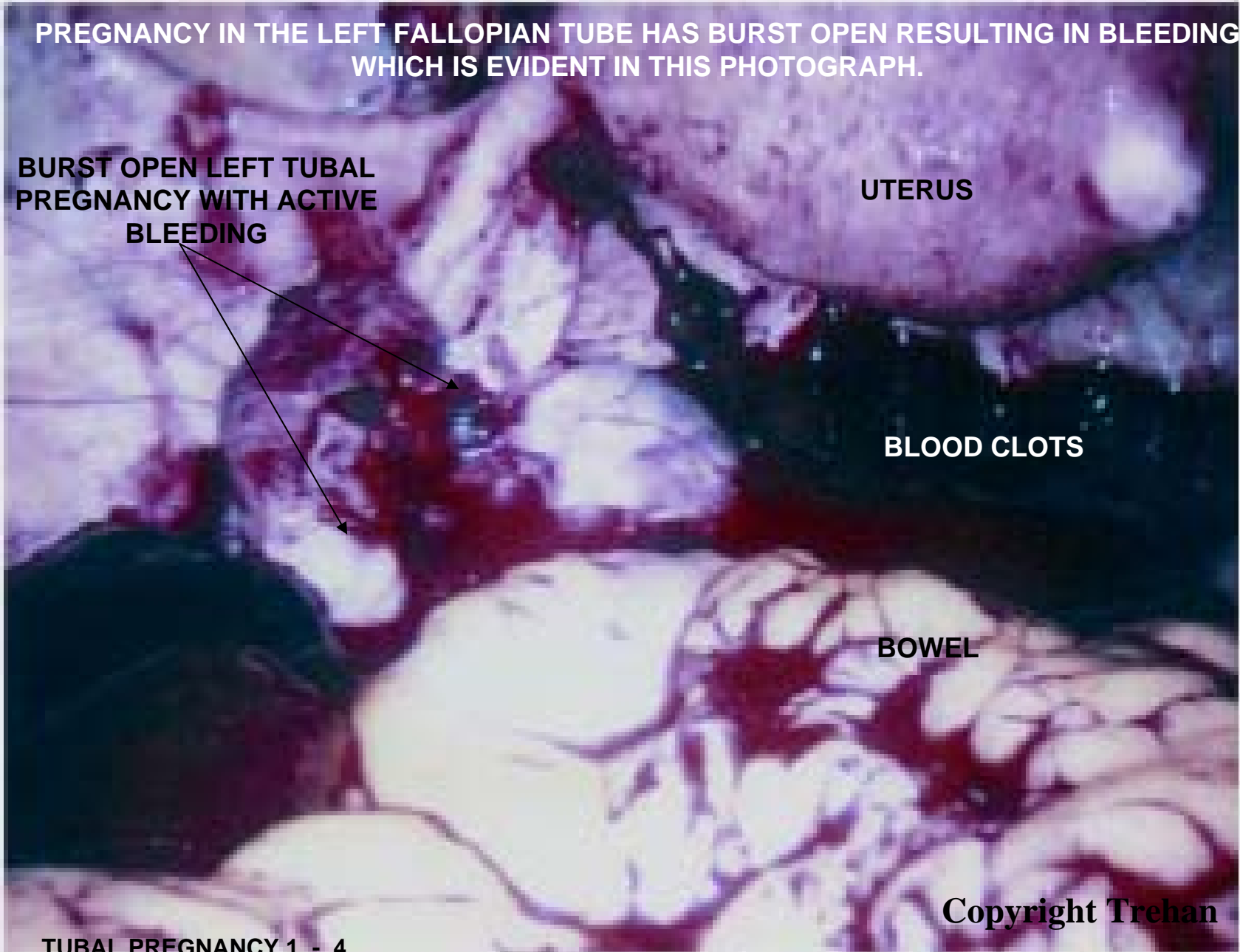
BURST OPEN LEFT TUBAL PREGNANCY WITH ACTIVE BLEEDING

UTERUS

BLOOD CLOTS

BOWEL

Copyright Trehan



PREGNANCY IN THE LEFT FALLOPIAN TUBE HAS BURST OPEN RESULTING IN BLEEDING AND DESTRUCTION OF PART OF THE FALLOPIAN TUBE CONTAINING PREGNANCY WHICH IS EVIDENT IN THIS PHOTOGRAPH.

RUPTURED PART OF LEFT TUBE WHERE PREGNANCY WAS HARBOURING

LEFT TUBE

UTERUS

BLOOD CLOT

OVARY

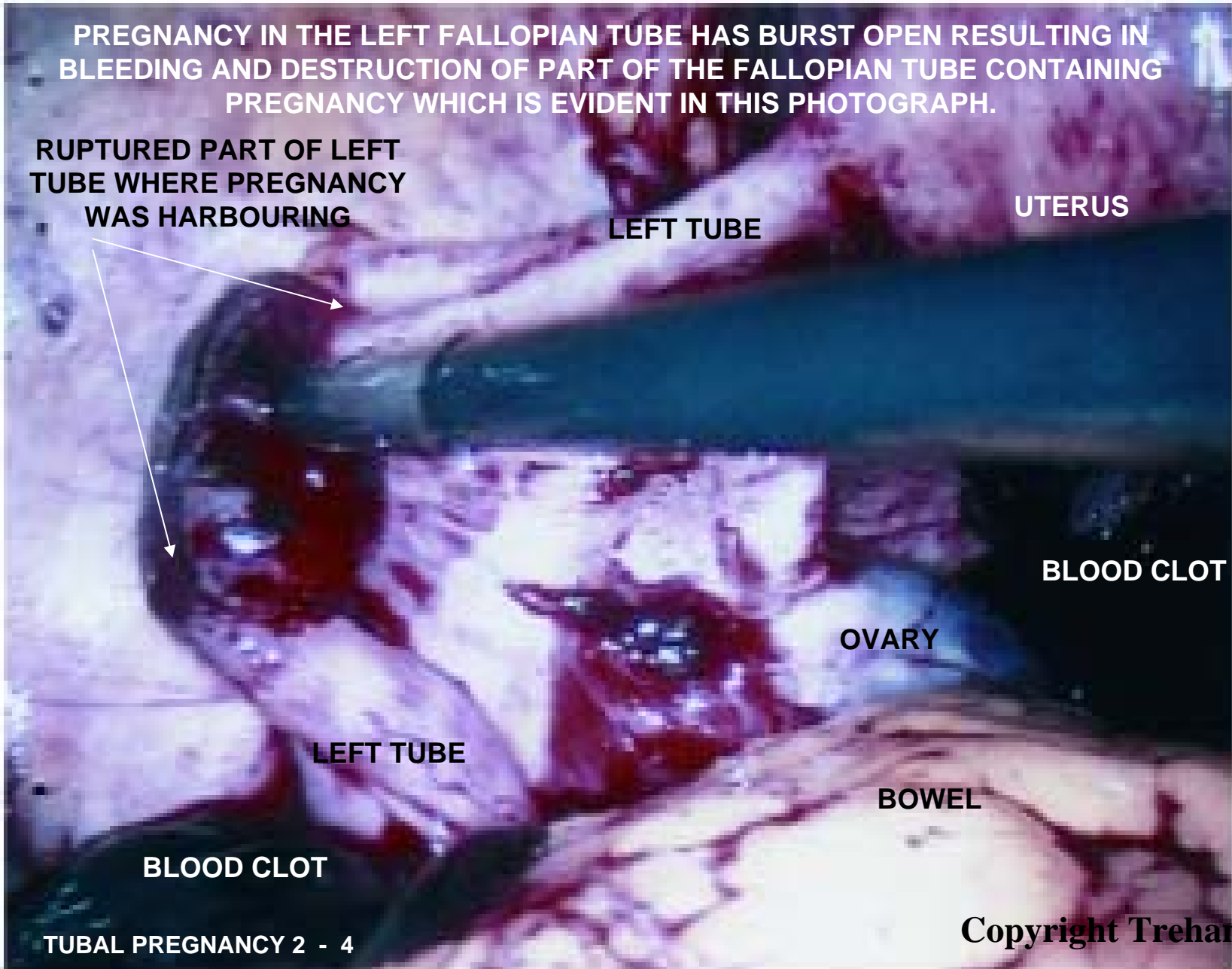
LEFT TUBE

BOWEL

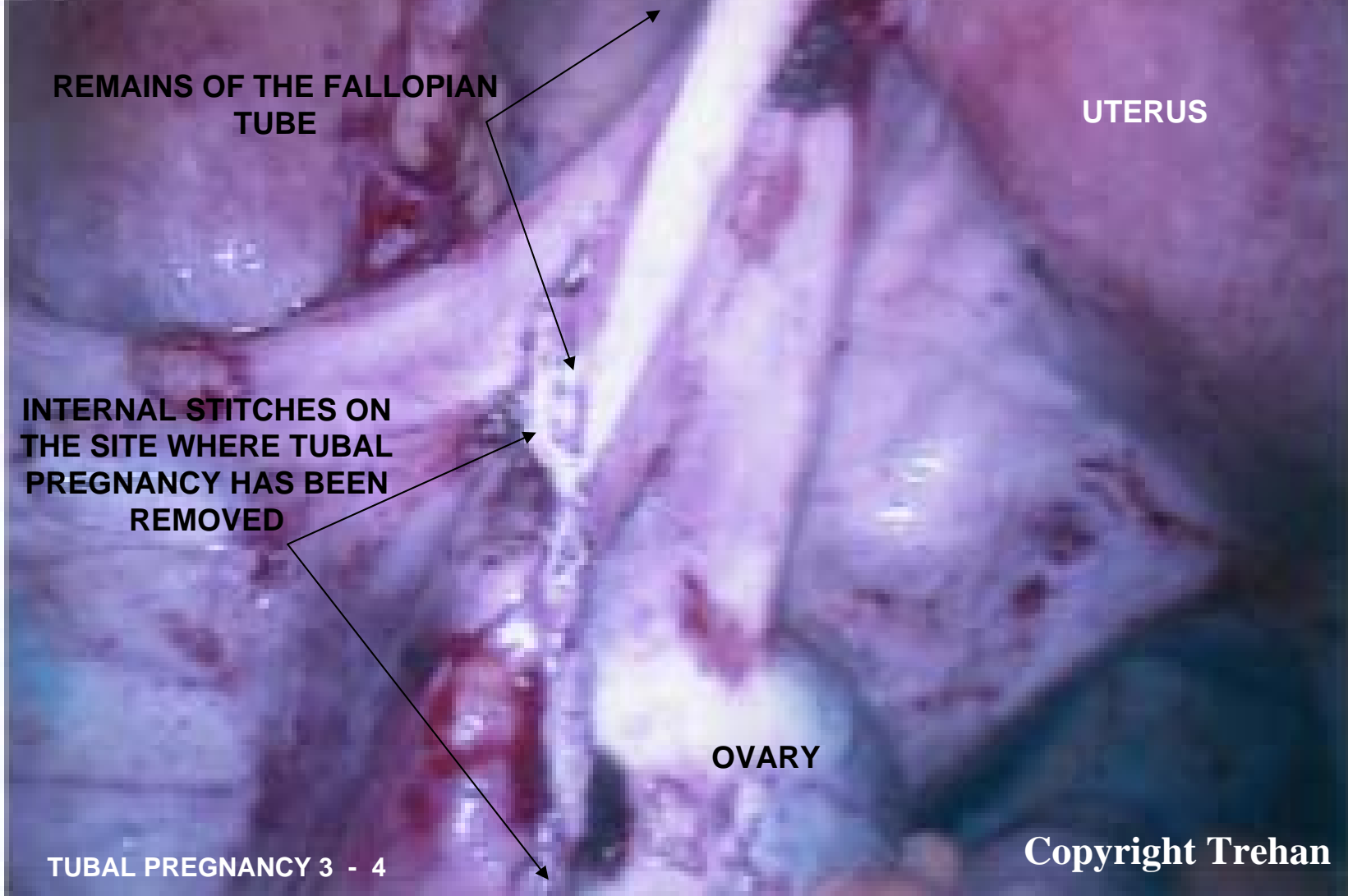
BLOOD CLOT

TUBAL PREGNANCY 2 - 4

Copyright Trehan



THIS PICTURE SHOWS THAT PREGNANCY AND MIDDLE PART OF THE LEFT FALLOPIAN TUBE WHERE PREGNANCY WAS HARBOURING HAVE BEEN REMOVED AND BLEEDING HAS BEEN CONTROLLED BY THE USE OF INTERNAL STITCHES AND MOST OF THE COLLECTED BLOOD IN THE PELVIS HAS BEEN REMOVED



REMAINS OF THE FALLOPIAN TUBE

UTERUS

INTERNAL STITCHES ON THE SITE WHERE TUBAL PREGNANCY HAS BEEN REMOVED

OVARY

Copyright Trehan

TUBAL PREGNANCY 3 - 4

**THIS IS THE FINAL PICTURE AFTER REMOVAL OF THE LEFT TUBAL PREGNANCY AND
CLEANING OF ALL THE BLOOD FROM THE PELVIS**

UTERUS

**RIGHT
FALLOPIAN
TUBE**

**REMAINS OF LEFT
FALLOPIAN TUBE**

**INTERNAL STITCHES ON
THE SITE WHERE TUBAL
PREGNANCY HAS BEEN
REMOVED**

LAPAROSCOPIC (KEYHOLE) MANAGEMENT OF RUPTURED ECTOPIC PREGNANCY IN THE OVARY

- The next six photographs belong to the same patient who has pregnancy in the left ovary (ectopic pregnancy) instead of in the uterus.
- It is very rare to have pregnancy in the ovary usually ectopic pregnancy is in the fallopian tube.
- Ovaries produce hormones and so every attempt should be made to preserve the ovary with the ectopic pregnancy.
- In this case the left ovary with ectopic pregnancy has given way (ruptured) resulting in active bleeding.
- The photographs demonstrate the keyhole technique of removing the ectopic pregnancy from the left ovary. The bleeding from the area of the ectopic pregnancy on the left ovary is controlled by cauterisation (heat treatment) The pelvic cavity is washed with saline solution and cleaned of all the blood.
- There is always a higher risk of future ectopic pregnancy.

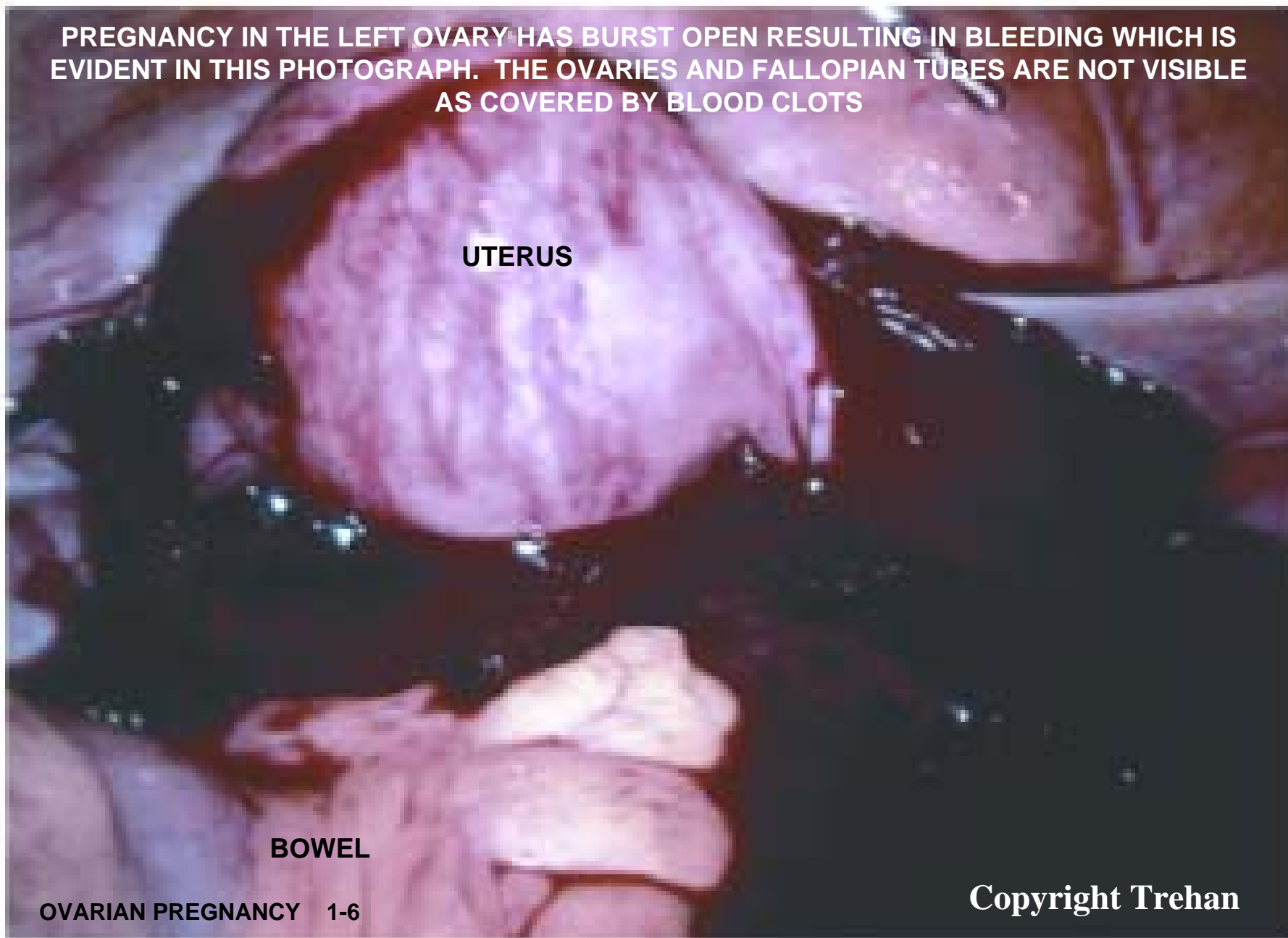PREGNANCY IN THE LEFT OVARY HAS BURST OPEN RESULTING IN BLEEDING WHICH IS EVIDENT IN THIS PHOTOGRAPH. THE OVARIES AND FALLOPIAN TUBES ARE NOT VISIBLE AS COVERED BY BLOOD CLOTS

UTERUS

BOWEL

OVARIAN PREGNANCY 1-6

Copyright Trehan



LEFT OVARY AND FALLOPIAN TUBE ARE VISIBLE IN THIS PHOTOGRAPH AFTER SOME OF THE BLOOD CLOTS HAVE BEEN REMOVED. FRESH BLEEDING IS CLEARLY VISIBLE COMING OUT OF THE OVARY DUE TO BURST OPEN/RUPTURED OVARIAN PREGNANCY

BURST OPEN OVARIAN PREGNANCY WITH ACTIVE BLEEDING

UTERUS

BLOOD CLOTS

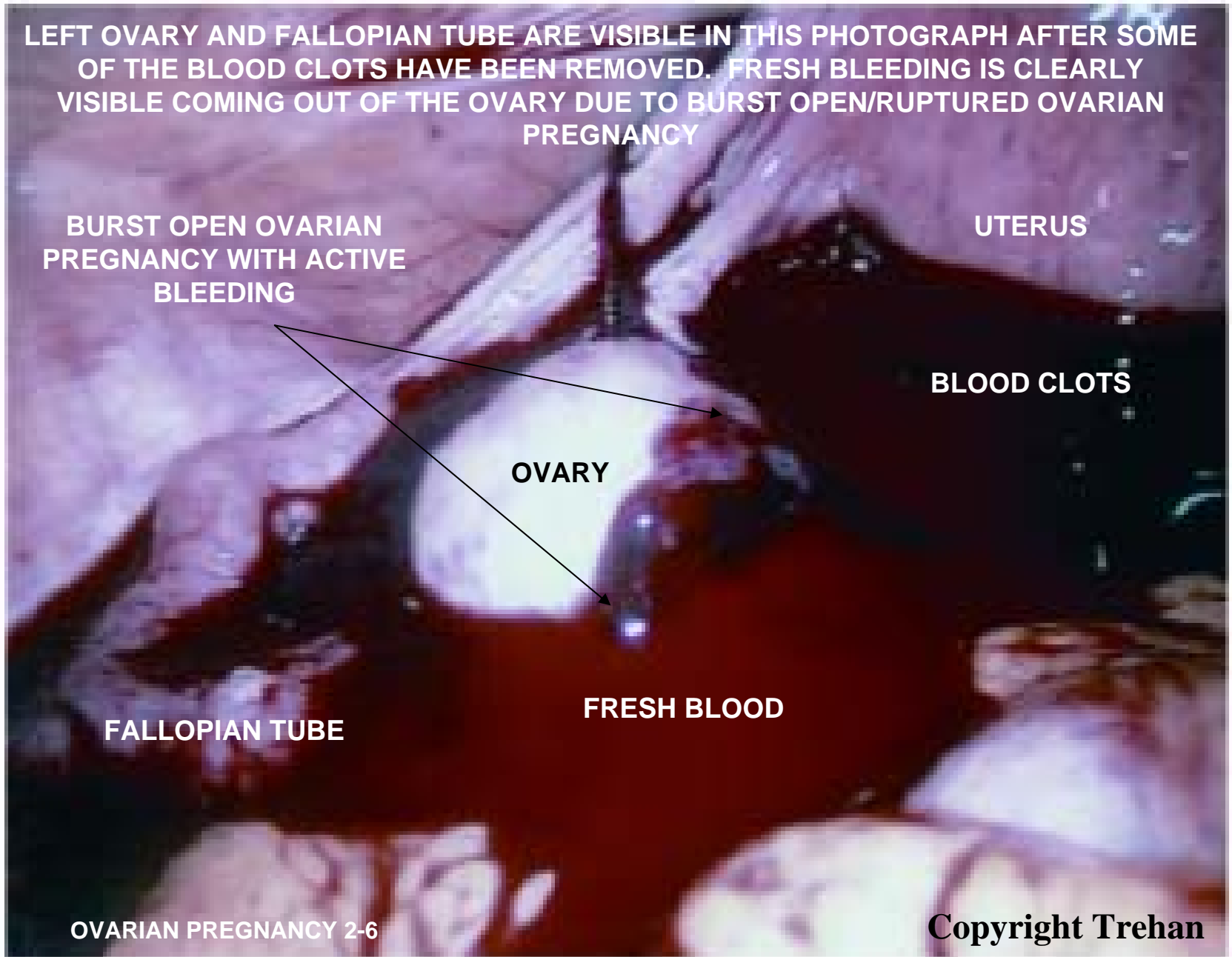
OVARY

FALLOPIAN TUBE

FRESH BLOOD

OVARIAN PREGNANCY 2-6

Copyright Trehan



FRESH BLEEDING IS CLEARLY VISIBLE COMING OUT OF THE OVARY DUE TO BURST OPEN/RUPTURED OVARIAN PREGNANCY

BURST OPEN OVARIAN PREGNANCY WITH ACTIVE BLEEDING

UTERUS

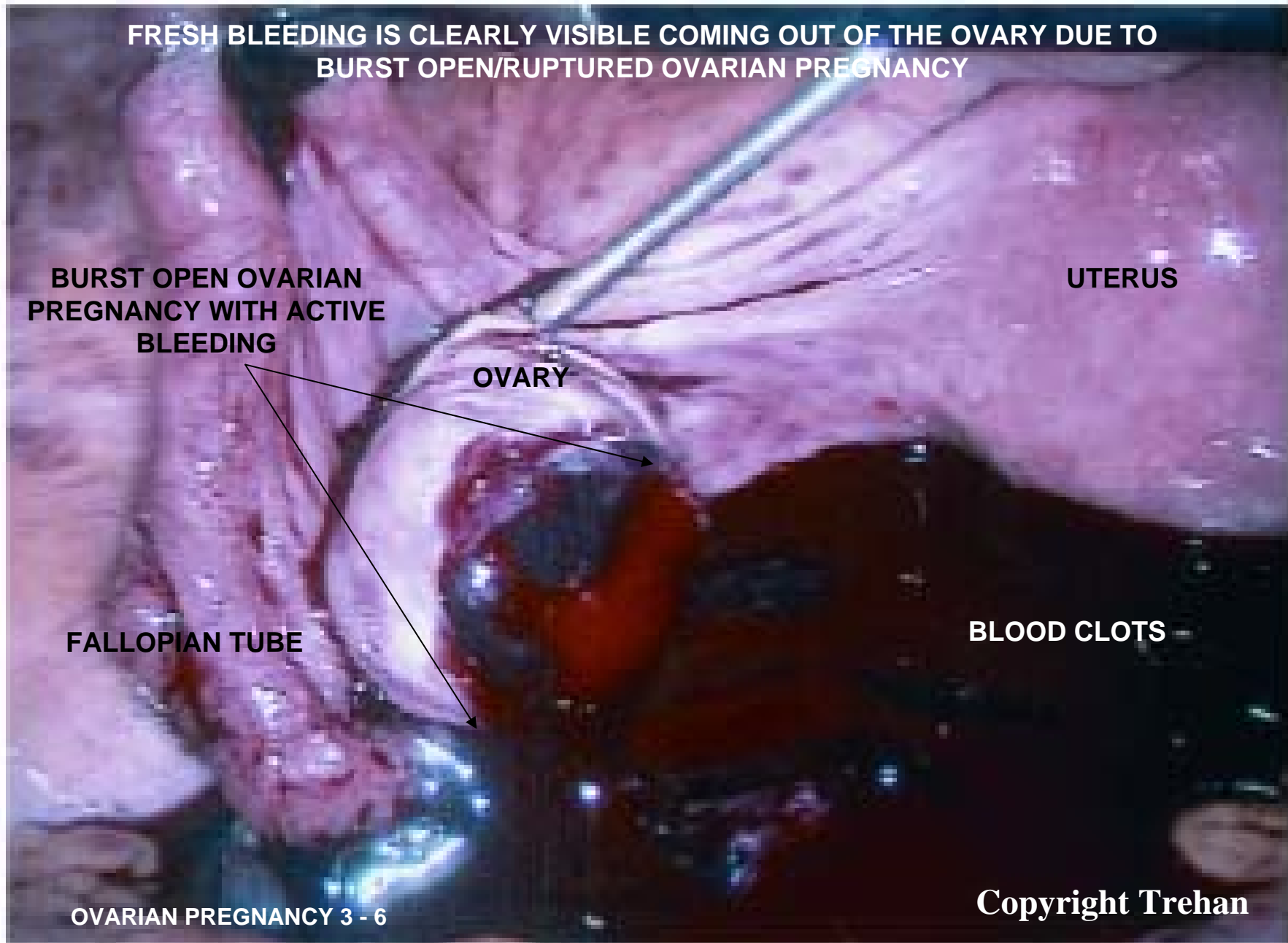
OVARY

FALLOPIAN TUBE

BLOOD CLOTS

OVARIAN PREGNANCY 3 - 6

Copyright Trehan



THIS PICTURE SHOWS OPENING/CAVITY IN THE OVARY WHERE THE PREGNANCY WAS DEVELOPING. OVARIAN PREGNANCY IS BEING REMOVED WITH KEYHOLE INSTRUMENT

OPENING/CAVITY IN THE
OVARY WHERE PREGNANCY
WAS DEVELOPING

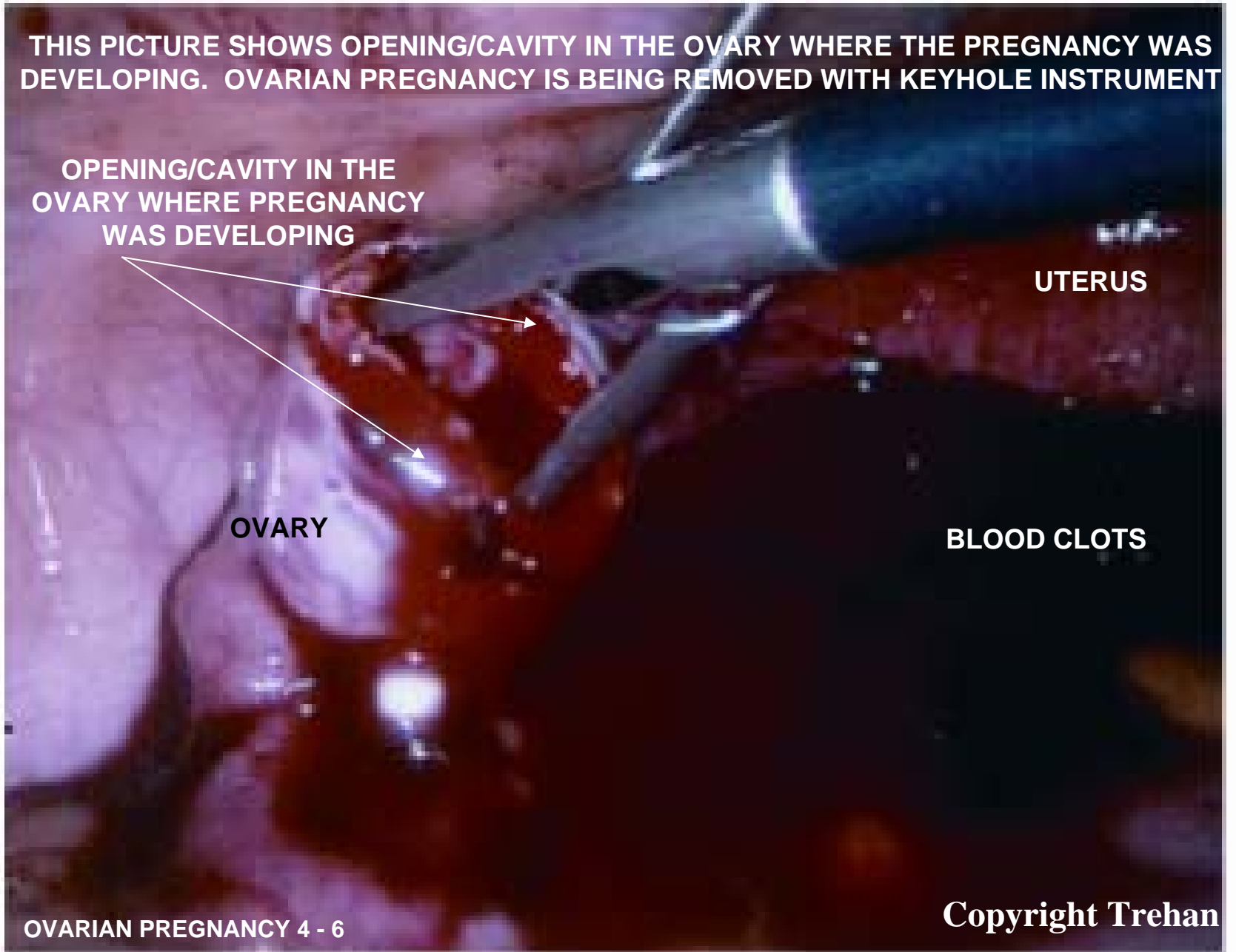
UTERUS

OVARY

BLOOD CLOTS

OVARIAN PREGNANCY 4 - 6

Copyright Trehan



THIS PICTURE SHOWS THAT PREGNANCY HAS BEEN REMOVED FROM THE OVARY AND BLEEDING HAS BEEN CONTROLLED BY THE USE OF HEAT (CAUTERY) AND MOST OF THE COLLECTED BLOOD IN THE PELVIS HAS BEEN REMOVED

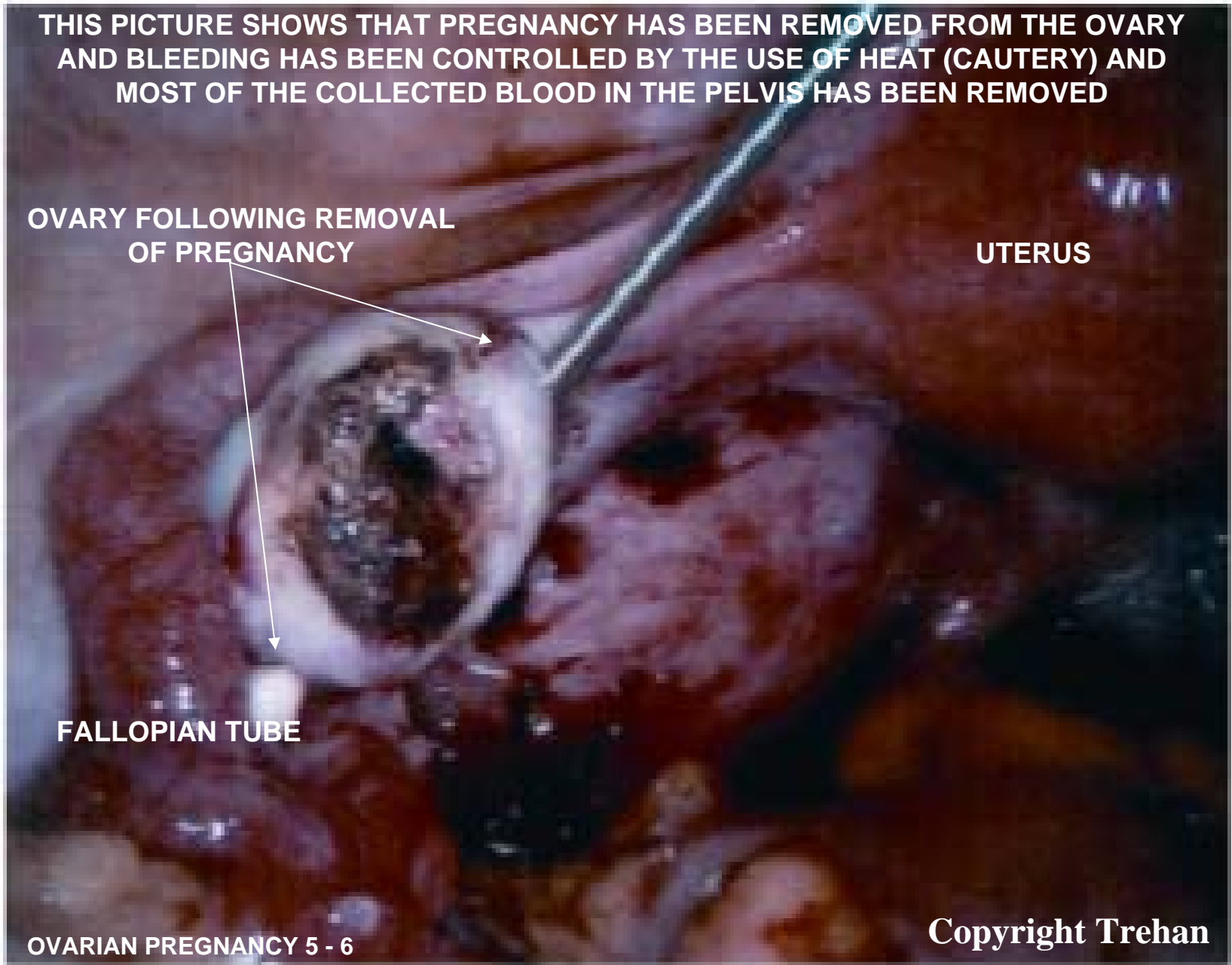
**OVARY FOLLOWING REMOVAL
OF PREGNANCY**

UTERUS

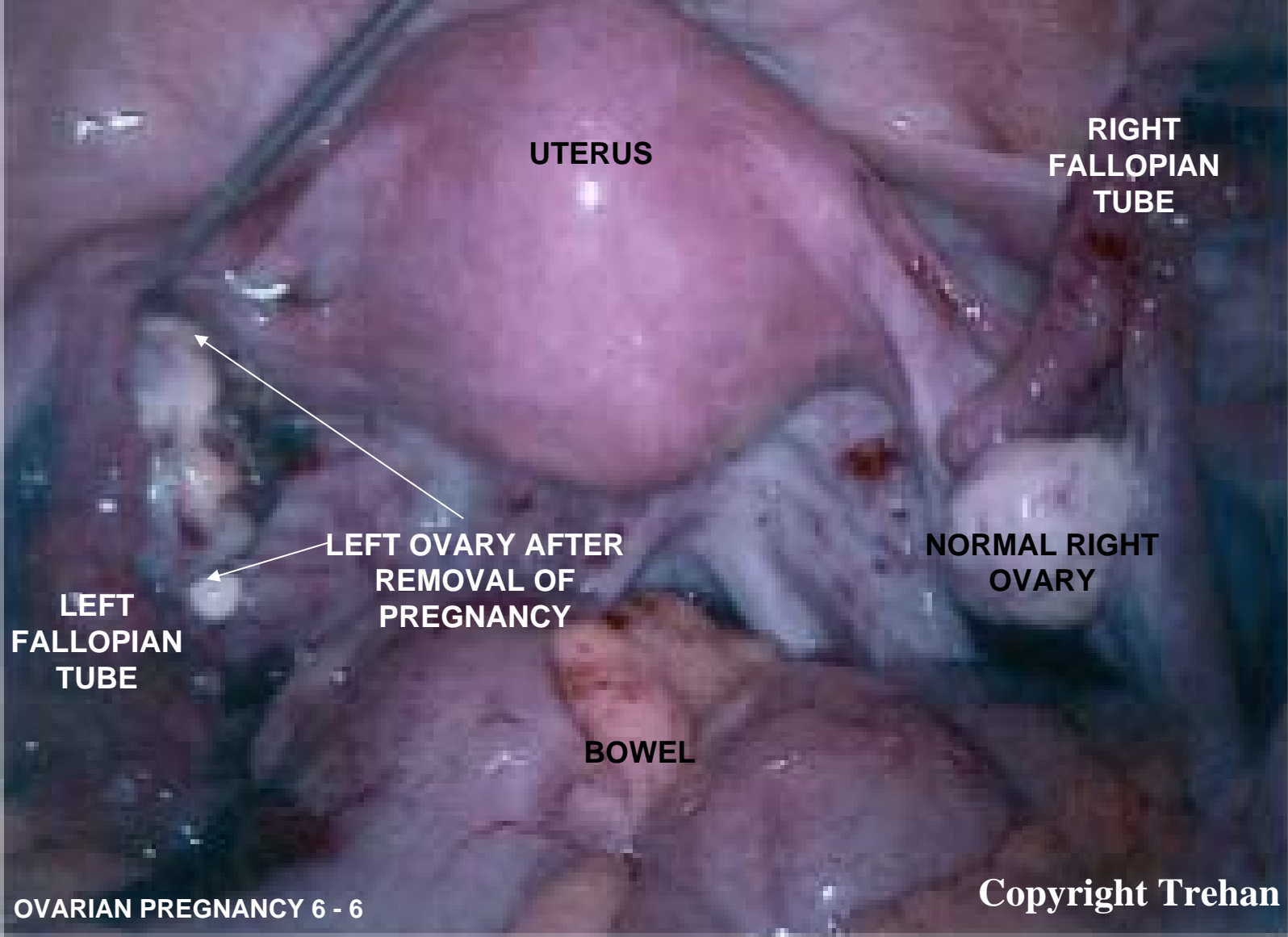
FALLOPIAN TUBE

OVARIAN PREGNANCY 5 - 6

Copyright Trehan



THIS IS THE FINAL PICTURE AFTER REMOVAL OF THE LEFT OVARIAN ECTOPIC PREGNANCY AND CLEANING OF ALL THE BLOOD FROM THE PELVIS



UTERUS

**RIGHT
FALLOPIAN
TUBE**

**LEFT OVARY AFTER
REMOVAL OF
PREGNANCY**

**NORMAL RIGHT
OVARY**

**LEFT
FALLOPIAN
TUBE**

BOWEL