

# Temporary ovarian suspension

A. K. Trehan

Dewsbury District Hospital, Dewsbury, England

## Keywords

ovarian adhesion, ovarian suspension, pelvic pain.

## ABSTRACT

**Background** Following the division of adhesions, ovarian cystectomys, and/or the excision or coagulation of endometriosis, pelvic pain may continue because of re-formation of adhesions between the posterior surface of the ovary and the ovarian fossa. Various methods of adhesion prevention, such as the use of Interceed, Intergel or heparinized saline etc., have proved unsuccessful. Temporary ovarian suspension is a simple technique of suspending the ovary, for 5-7 days, by attachment to the anterior abdominal wall. This allows separation of the raw area on the ovary and the ovarian fossa until surface epithelialization has occurred. When the suture is removed, the ovary falls back to its anatomical position.

**Objective** To describe and discuss this simple technique of suspending the ovaries.

**Intervention** The anterior abdominal wall is transilluminated with the laparoscope to demonstrate any major blood vessels, especially the inferior epigastric vessels. The junction of the lateral one-quarter and the medial three-quarters, approximately 1 inch above the inguinal ligament is the site on the anterior abdominal wall used for ovarian suspension. Non-absorbable number 0 Prolene on a straight needle is used for suturing. The needle is pushed into the abdominal cavity at the abovementioned site; it picks up the ovary and comes out of the abdominal wall at the same site. The thread is tied on the anterior abdominal wall, with appropriate adjustment of the tension. The stitch is covered with a transparent dressing which is left in position until the day of removal of the stitch.

## Correspondence

A. K. Trehan, Dewsbury District Hospital, Halifax Road, Dewsbury, West Yorkshire WF13 4HS, England.

Accepted for publication May 2002 .

## INTRODUCTION

Following division of pelvic adhesions, ovarian cystectomy, and excision and coagulation of endometriosis, infertility, chronic pelvic pain or dyspareunia may continue because of re-formation of adhesions between the posterior surface of the ovary and the ovarian fossa.

I describe here an innovative surgical technique for temporarily separating the raw surfaces on the ovary and the ovarian fossa following the above procedures, during the healing phase (5-7 days) until surface epithelialization has occurred. This should help to prevent formation of adhesions between the ovary and ovarian fossa. The technique is termed 'temporary ovarian suspension'.

In 1968, with similar aims in mind, Palmer described a technique of temporary ovarian suspension where he attached the upper pole of the ovary to the lateral pelvic wall using, single no.1 plain catgut.<sup>1</sup> This technique for temporarily suspending the ovary did not become popular, and it was later abandoned as, at second-look, ovaries were found to be firmly adherent to the site of fixation.

## MATERIALS AND METHODS

### Description of technique

A point at the junction of the lateral one-quarter and medial three-quarters of a line 2.5 cm (1 inch) above the

inguinal ligament is identified as the point for ovarian suspension. The anterior abdominal wall is transilluminated with the laparoscope at this point, to demonstrate any major blood vessels. Normally, the inferior epigastric vessels will lie medially by this point. A non-absorbable suture on a strong straight needle is used; I use no. 0 Prolene.

The needle is passed percutaneously into the abdominal cavity at the point of transillumination, perpendicular to the skin. The entry into the peritoneal cavity is observed on the monitor. Using a laparoscopic needle-holder the suture is passed through the ovary once. Care is taken to keep away from the ovarian pampiniform plexus. The needle is passed back out of the abdomen, adjacent to the entry point. The tension of the suture is adjusted, while the ovary is observed on the monitor to avoid torsion, and the suture is tied on the anterior abdominal wall (see Fig. 1).

The stitch is covered with a transparent dressing, which is left in position until the day of removal of the stitch in the outpatient clinic.

The procedure is repeated on the other side if necessary.

#### Patients

Between June 2000 and June 2001, 35 patients underwent temporary ovarian suspension at Dewsbury and District General Hospital. The technique was undertaken as an adjunctive procedure to various gynaecological operations mentioned in Table 1.

Table 1 Details of various gynaecological operations for which temporary ovarian suspension was used as an adjunctive procedure between June 2000 and June 2001

Condition	Operation	No. of patients	Postoperative stay (total for all patients), days	Complications
Endometriosis	Excision and coagulation of pelvic endometriosis <i>with or without</i>	24	25	Nil
	Excision or coagulation of ovarian chocolate cyst <i>with or without</i>			
	Division of endometriotic adhesions			
Pelvic adhesions*	LAVH and excision of endometriosis	3	4	Nil
	Division of adhesions	4	4	Nil
Infertility†	Tubal surgery	2	2	Nil
Ovarian cyst <i>with or without</i> adhesions	Ovarian cystectomy <i>with or without</i> adhesiolysis	2	2	Nil

LAVH, laparoscopic-assisted vaginal hysterectomy.

\*Following surgery e.g. hysterectomy, or pelvic inflammatory disease.

† Both patients achieved pregnancy.

#### RESULTS

As this technique was applied as an adjunct to other operations, it is difficult to separate the outcome for temporary ovarian suspension from that for the whole procedure. During the period of study, two patients had tubal surgery with temporary ovarian suspension; both have achieved pregnancy. We did not encounter any complication related to this procedure.

All patients were discharged home after an overnight stay, except for two who remained in hospital for 2 days.

#### DISCUSSION

The ovaries lie in a shallow peritoneal fossa on the lateral pelvic wall. Adhesion of the ovary to this fossa is not uncommon. This occurs as a consequence of pelvic inflammatory disease, endometriosis, or post-surgical trauma to the peritoneum of the fossa or the surface of the ovary, for example, following ovarian cystectomy,<sup>2,4</sup> excision of endometriosis,<sup>5,6</sup> adhesiolysis<sup>7</sup> or total abdominal hysterectomy.<sup>8</sup> In some cases the specific underlying cause of adhesion is unclear.

Whatever the cause, the clinical consequences of adhesion formation may be chronic pelvic pain, infertility and dyspareunia. Adhesions were identified as the primary cause of chronic pelvic pain in 13-26% of females.<sup>9-12</sup> They are a major cause of infertility in females:<sup>13</sup> 40% of female infertility is related to adhesions.<sup>14-16</sup> Pain during coitus is frequently reduced after

## TEMPORARY OVARIAN SUSPENSION

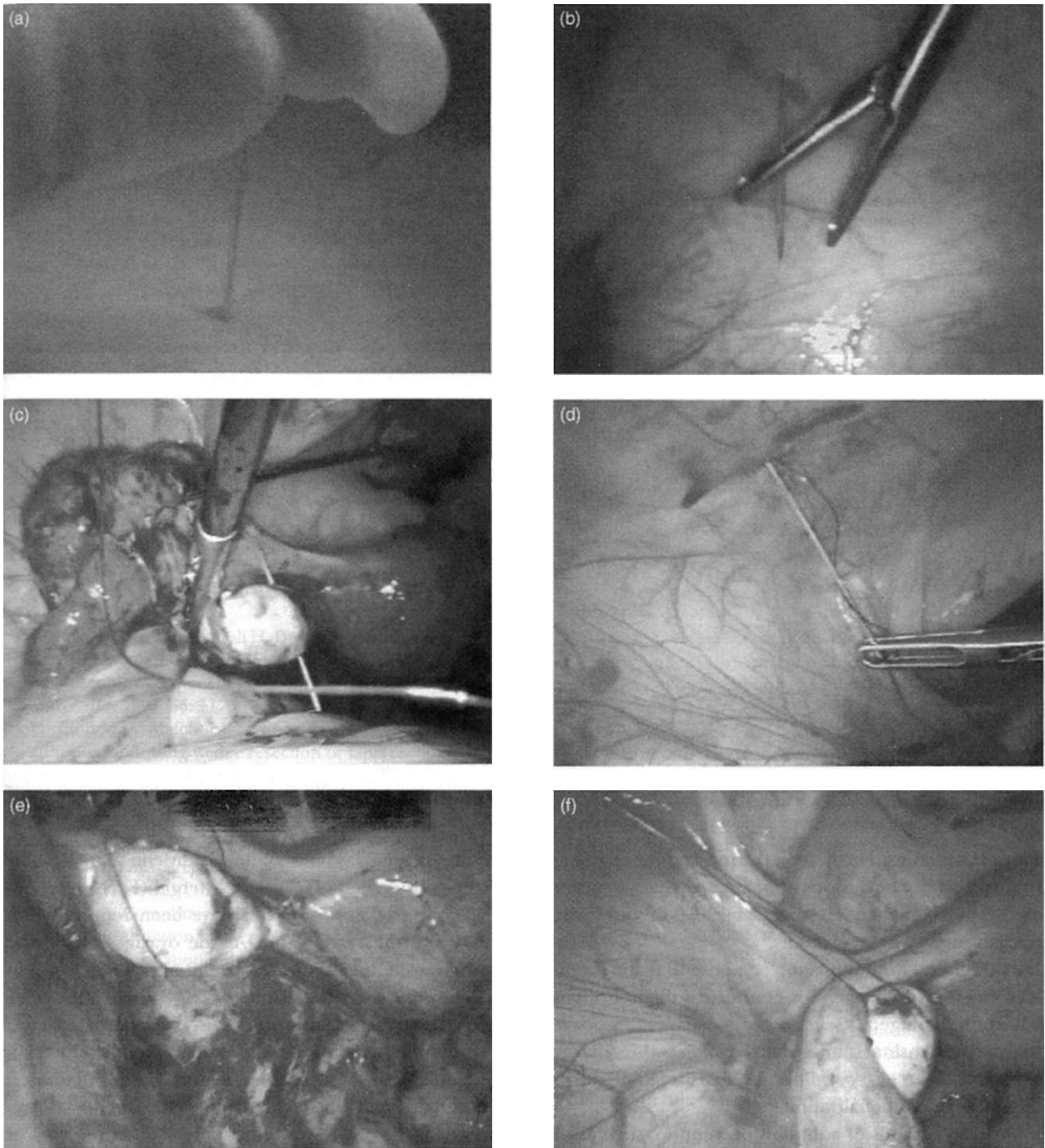


Figure 1 (a) Transillumination of anterior abdominal wall and insertion of needle, (b) Entry of needle into peritoneal cavity, (c) Needle through left ovary, (d) Needle passed back out of the abdomen adjacent to the entry point, (e) Ovary pulled away from raw ovarian fossa, (f) Tension of the suture adjusted. *Continued, panels (g)-(i), next page.*

lysis of pelvic adhesions.<sup>17</sup> Whether or not ovarian adhesions affect ovarian function is still uncertain.

It is well recognised that division of adhesions is usually followed by re-formation of adhesions between the

ovary and ovarian fossa. This is because the ovary rests on the surface of the fossa and the raw surfaces are in close proximity. Moreover the ovary, unlike the peritoneum, is covered by a simple mesothelial layer, with no underlying

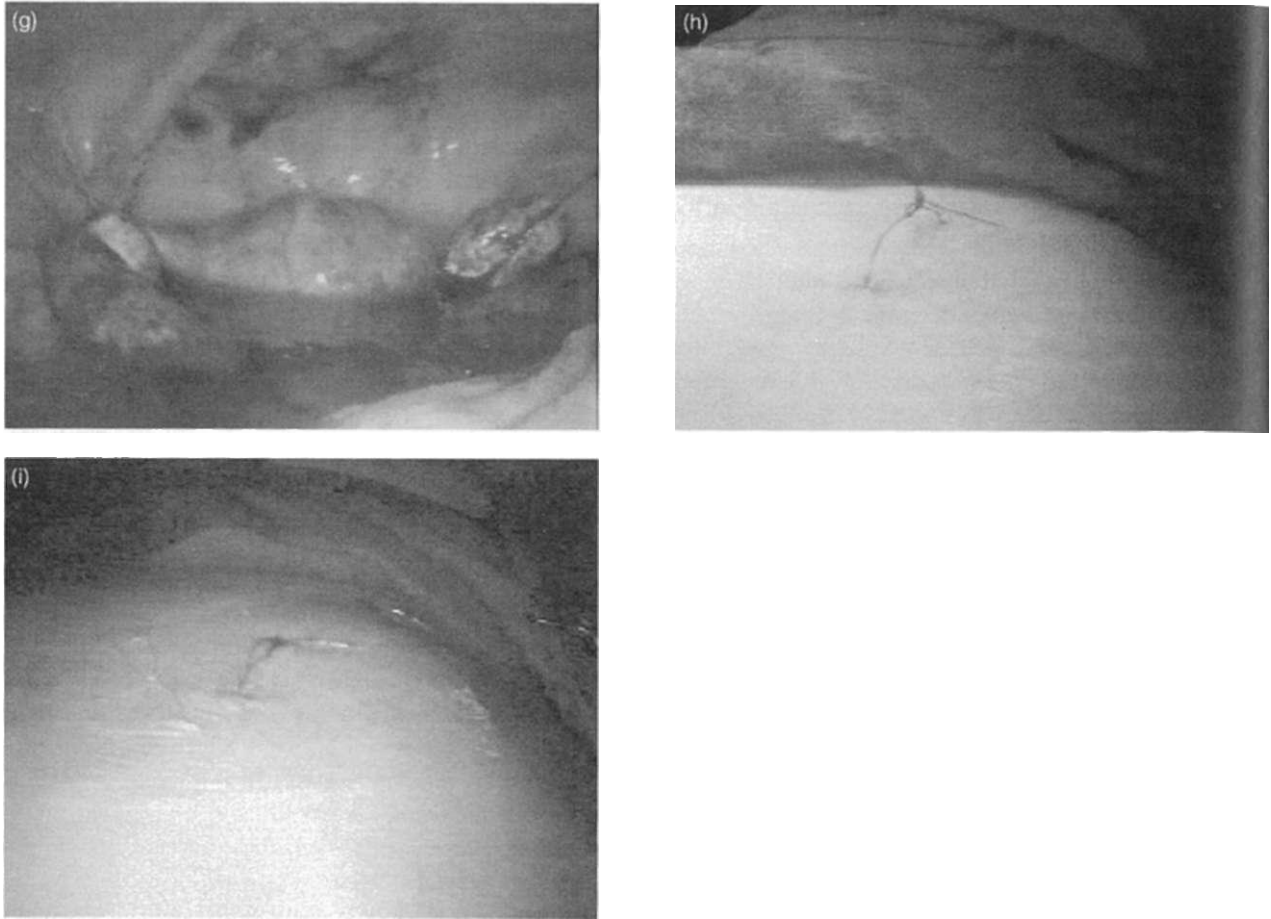


Figure 1 *continued* (g) Suspended both ovaries, (h) Suture tied on anterior abdominal wall, (i) Suture is covered with transparent dressing.

support structure. The ovary is the most common site for re-formation of adhesions after reconstructive surgery of the pelvis,<sup>18,19</sup> and it occurs in 90% of cases after ovarian surgery by laparotomy.<sup>20</sup>

The general wound-healing response to tissue trauma is formation of collagenous connective tissue bridging adjacent damaged tissue or organs.<sup>21-22</sup> Temporary ovarian suspension is an attempt to keep the adjacent damaged organ ovary and ovarian fossa separate during the phase of epithelialization.

Various methods of adhesion prevention, such as the use of microsurgical techniques, gentle handling of tissues, meticulous haemostasis, removal of blood clots,<sup>23</sup> prevention of tissue drying with constant tissue irrigation, removal of foreign material and covering the raw peritoneal area with tissue grafts, have been used. In addition, numerous adjuvants have been used to reduce postoperative adhesions. These include anticoagulants,<sup>24</sup> fibrinolytic agents,<sup>25</sup> high molecular weight Dextran,<sup>26</sup> hydrocortisone,<sup>27</sup> calcium-channel blockers,<sup>28</sup> progesterone,<sup>29</sup> amniotic

membrane grafts,<sup>30</sup> polytetrafluoroethylene surgical membrane,<sup>31</sup> Interceed (TC7)<sup>6</sup> and Intergel (FeHA).<sup>32,33</sup>

Varying degrees of success have been reported with the use of these adjuvants. As the ovaries rest on the ovarian fossa, the adjuvants are not always successful in preventing ovarian adhesion.

Temporary ovarian suspension is a simple surgical technique of keeping the ovary apart from the ovarian fossa during the early healing phase. Normal anatomical relations should be restored once the stitches are removed on day 5-7. We select day 5-7 for removal of stitches as adhesions frequently develop during the first 3-5 days, following surgery, the crucial phase of peritoneal repair.<sup>34-35</sup>

For ethical reasons, we have not been able to carry out repeat laparoscopy in these patients and thus are unable to report on outcomes. However, none of the patients have required repeat laparoscopy for pain. Two of our patients who underwent temporary ovarian suspension with tubal surgery have both achieved pregnancy.

I feel that temporary ovarian suspension should be considered when ovarian adhesion is a possibility especially in cases where antiadhesive adjuvants are not used. However I accept that further study is needed to confirm its efficacy.

### Conclusions

Temporary ovarian suspension is safe, simple and likely to be an effective technique in preventing postoperative adhesions between the ovaries and the ovarian fossa. It is a useful adjunctive treatment to various gynaecological operations, where ovarian adhesion to the ovarian fossa is likely.

### REFERENCES

- 1 Palmer R, Le traitement chirurgical des sterilités tubaires. *Bulletin de la Federation des Societes de Gynecologic et d'Obstetrique de Langue Francaise* 1968; **20**:130.
- 2 Canis M, Mage G, Wattiez A, Chapron Setna, Pouly JL, Bassil S. Second-look laparoscopy after laparoscopic cystectomy of large ovarian endometriomas. *Fertility and Sterility* 1992; **58**: 617-19.
- 3 Gurgan T, Kismisci H, Yarali H, Develioglu O, Zeyneloglu H, Aksu T. Evaluation of adhesion formation after laparoscopic treatment of polycystic ovarian disease. *Fertility and Sterility* 1991; **56**:1176-8.
- 4 Portuondo JA, Melchor JC, Neyro JL, Alegre A. Periovarian adhesions following wedge resection or laparoscopic biopsy. *Endoscopy* 1984; **16**:143-5.
- 5 Gurgan T, Urman Butler Yarali H. Adhesion formation and reformation after laparoscopic removal of ovarian endometriomas. *Journal of the American Association of Gynecologic Laparoscopists* 1996; **3**: 389-92.
- 6 Sekiba K. The Obstetrics and Gynecology Adhesion Prevention Committee. Use of Interceed (TC7) absorbable adhesion barrier to reduce post operative adhesion reformation in infertility and endometriosis surgery. *Obstetrics and Gynecology* 1992; **79**: 518-22.
- 7 Diamond E. Lysis of postoperative pelvic adhesions in infertility. *Fertility and Sterility* 1979; **31**: 287-95.
- 8 Strieker B, Blanco J, Fox HE. The gynecologic contribution to intestinal obstruction in females. *Journal of the American College of Surgery* 1994; **178**: 617-20.
- 9 Goldstein DP, DeChoinoky C, Emans SJ, Leventhal JM. Laparoscopy in the diagnosis and management of pelvic pain in adolescents. *Journal of Reproductive Medicine* 1980; **24** (6): 51-6.
- 10 Malinak LR. Operative management of pelvic pain. *Clinics in Obstetrics and Gynecology* 1980; **23** (1): 191-200.
- 11 Ranaer, M, ed. *Pelvic Pain in Women*. New York: Springer-Verlag, 1981: 78-92.
- 12 Rapkin AJ. Adhesion and pelvic pain retrospective study. *Obstetrics and Gynecology* 1986; **68** (1), 13-15.
- 13 Drake TS, Grunert GM. The unsuspected pelvic factor in the infertile investigation. *Fertility and Sterility* 1980; **34** (1): 27-31.
- 14 Grimes EM, Richardson MR. Management of the infertile couple. In: Sciarra JJ, ed. *Gynecology and Obstetrics*. Philadelphia: J B Lippincott, 1991:1-21.
- 15 Wilson EA. The infertile couple: interview and physical examination. In: Givens JR, ed. *The Infertile Female*. Chicago: Year Book Medical Publishers, 1979: Chapter 2.
- 16 Mishell DR, Davajan V. Evaluation of the infertile couple. In: Mishell DR, Davajan V, Lobo R, eds. *Contraception and Reproductive Endocrinology*. 3rd edn. Boston: Blackwell Scientific Publishing, 1991: 557-70.
- 17 Chan CLK, Wood C. Pelvic adhesiolysis - the assessment of symptom relief by 100 patients. *Australian and New Zealand Journal of Obstetrics and Gynaecology* 1985; **25**: 295-8.
- 18 Interceed (TC7) Adhesion Barrier Study Group. Prevention of postsurgical adhesions by Interceed (TC7), an absorbable adhesions barrier: a prospective, randomised multicentre clinical study. *Fertility and Sterility* 1989; **51** (6): 933-8.
- 19 Diamond MP, Daniell JF, Feste J, Surrey MW, McLaughlin DS, Friedman S, Vaughn WK, Martin DC. Adhesion reformation and de novo adhesion formation after reproductive pelvic surgery. *Fertility and Sterility* 1987; **47** (5): 864-6.
- 20 Pittaway DE, Daniell JF, Maxon WS. Ovarian surgery in an infertility patient as an indication for a short interval second look laparoscopy: a preliminary study. *Fertility and Sterility* 1985; **44** (5): 611-14.
- 21 Goldberg EP, Sheets JW, Habal MB. Peritoneal adhesions - prevention with the use of hydrophilic polymer coating. *Archives of Surgery* 1980; **115**: 776-80.
- 22 Duncan DA, Yacoobi Y, Golberg EP, Mines M, Carmichael MJ. Prevention of postoperative peri-cardial adhesions with hydrophilic polymer solution. *Journal of Surgical Research* 1980; **45**: 44-9.
- 23 Gornel V. Peritoneal fibrinolysis and adhesion formation. In: DiZerega GS, ed. *Peritoneal Surgery*. New York: Springer-Verlag, 2000: vii-xi.
- 24 Pfeffer WH. Adjuvants in tubal surgery. *Fertility and Sterility* 1980; **33**: 245-56.
- 25 Spagna PM, Peskin GW. An experimental study of fibrinolysis in the prophylaxis of peritoneal adhesions. *Surgery, Gynecology, and Obstetrics* 1961; **113**: 497-511.
- 26 Rosenberg S, Board J. High molecular weight Dextran in human infertility surgery. *American Journal of Obstetrics and Gynecology* 1984; **48**: 380-5.
- 27 Swolin K. the Einwirkung Von Grossen, intraperitonealen dosen Glukokortikoid auf die bildung von postoperativen adhasionen. *Acta Obstetrica et Gynecologica Scandinavica* 1988; **46**: 204-18. [In German.]
- 28 Steinleitner A, Lambert H, Montoro L, Kelly E, Swanson J, Sueldo C. The use of calcium channel blockade for the prevention of post operative adhesion formation. *Fertility and Sterility* 1988; **50**: 818-21.
- 29 Blauer KL, Collins RL. The effect of intraperitoneal progesterone on post operative adhesion Brown formation in rabbits. *Fertility and Sterility* 1988; **49**: 144-9.

**A. K. TREHAN**

- 30 Badawy SZ, Baggish MS, Elbakry MM, Baltoyannis P. Evaluation of tissue healing and adhesion formation after an intraabdominal amniotic membrane graft in the rat. *Journal of Reproductive Medicine* 1989; **34**: 198-202.
- 31 Boyers SP, Diamond MP, DeCherney AH. Reduction of postoperative pelvic adhesions in the rabbit with Gore-Tex surgical membrane. *Fertility and Sterility* 1998; **49**: 1066-70.
- 32 Wiseman DM, Trout JR, Diamond MP. The rate of adhesion developments and the effects of crystalloid solutions on adhesion development in pelvic surgery. *Fertility and Sterility* 1998; **70**: 702-11.
- 33 Thornton MH, Johns DB, Campeau JC, *et al* Clinical evaluation of 0.5% ferric hyaluronate adhesions prevention gel for the reduction of adhesion following peritoneal cavity surgery: open-label pilot study. *Human Reproduction* 1998; **13**: 1480-5.
- 34 Ellis H, Harrison W, Hugh TB. The healing of peritoneum under normal and pathological conditions. *British Journal of Surgery* 1965; **52**: 471-6.
- 35 Roftery AT, Milligan DW. Observations on the pathogenesis of peritoneal adhesions; a light and electron microscopic study. *British Journal of Surgery* 1974; **61**: 274-80.