

**LAPAROSCOPIC (KEYHOLE) OPERATION  
FOR  
TILTED (RETROVERTED) WOMB  
(VENTROSUSPENSION)**

**MR A K TREHAN, FRCOG, FRCS (Edin)**

**CONSULTANT MINIMAL ACCESS GYNAECOLOGIST  
WITH SPECIAL INTEREST IN ENDOMETRIOSIS**

**DEWSBURY & DISTRICT HOSPITAL  
WEST YORKSHIRE  
ENGLAND, UK**

**LAPAROSCOPIC (KEYHOLE) OPERATION FOR  
TILTED (RETROVERTED) WOMB (VENTROSUSPENSION)**

**THE TEXT IN PREPARATION MOVE ON  
TO THE NEXT SLIDE**

**THIS PHOTOGRAPH DEMONSTRATES A TILTED WOMB WHICH IS POINTING BACK TOWARDS THE SPINE**

**LT ROUND  
LIGAMENT**

**RT ROUND  
LIGAMENT**

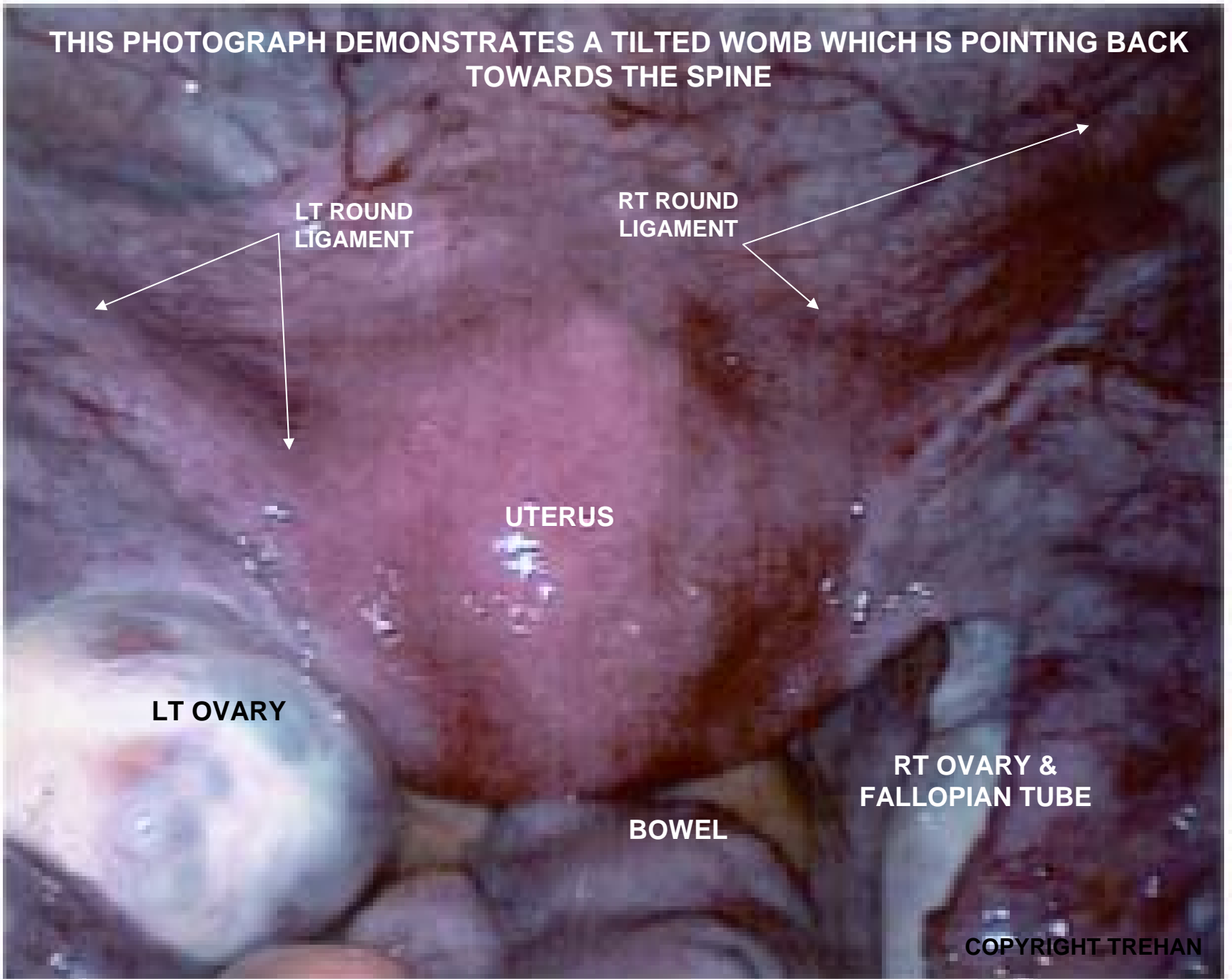
**UTERUS**

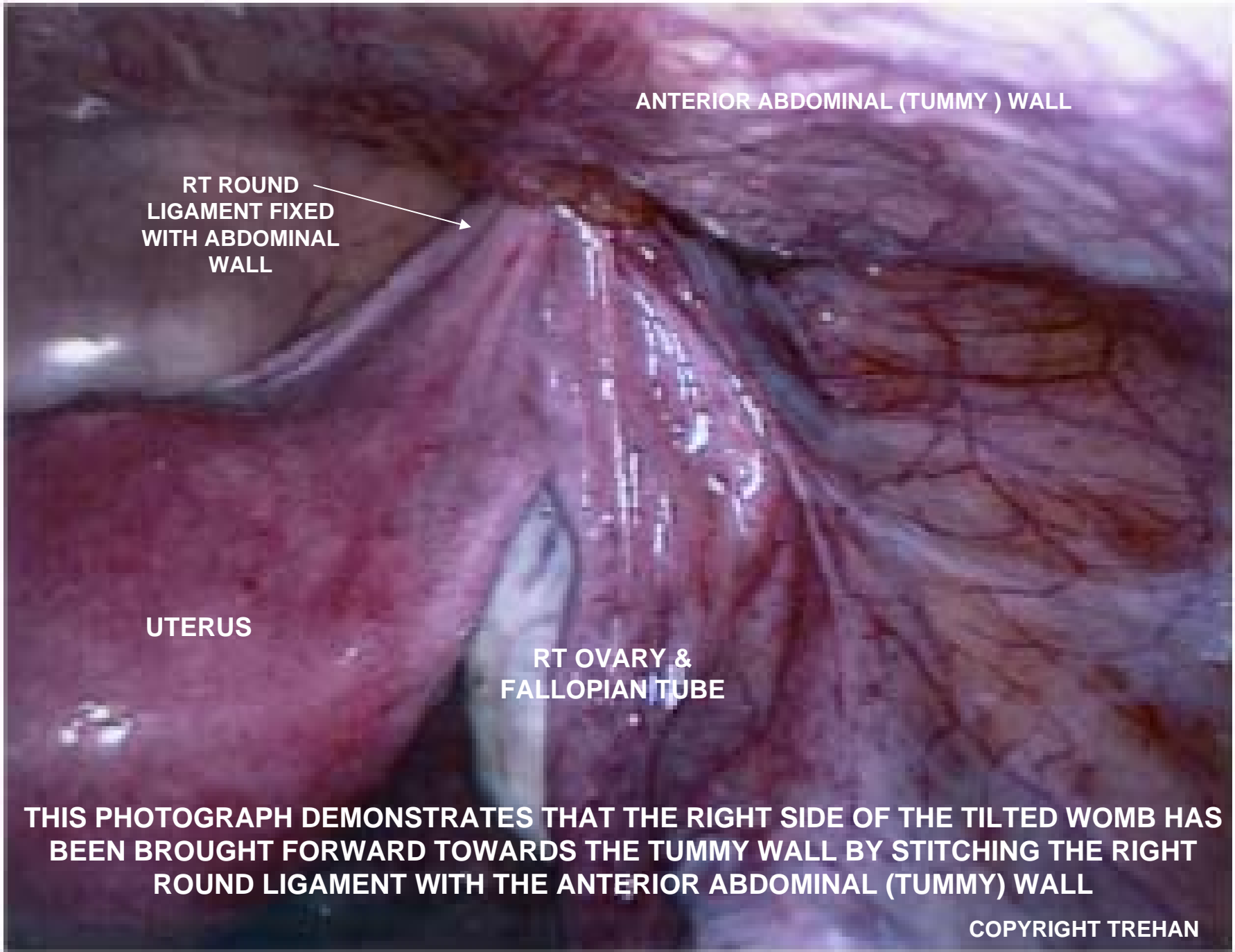
**LT OVARY**

**RT OVARY &  
FALLOPIAN TUBE**

**BOWEL**

**COPYRIGHT TREHAN**





ANTERIOR ABDOMINAL (TUMMY ) WALL

RT ROUND  
LIGAMENT FIXED  
WITH ABDOMINAL  
WALL

UTERUS

RT OVARY &  
FALLOPIAN TUBE

**THIS PHOTOGRAPH DEMONSTRATES THAT THE RIGHT SIDE OF THE TILTED WOMB HAS BEEN BROUGHT FORWARD TOWARDS THE TUMMY WALL BY STITCHING THE RIGHT ROUND LIGAMENT WITH THE ANTERIOR ABDOMINAL (TUMMY) WALL**

COPYRIGHT TREHAN



ANTERIOR ABDOMINAL (TUMMY) WALL

LT ROUND  
LIGAMENT FIXED  
WITH ABDOMINAL  
WALL

UTERUS

LT OVARY &  
FALLOPIAN TUBE

**THIS PHOTOGRAPH DEMONSTRATES THAT THE LEFT SIDE OF THE TILTED WOMB HAS BEEN BROUGHT FORWARD TOWARDS THE TUMMY WALL BY STITCHING THE LEFT ROUND LIGAMENT WITH THE ANTERIOR ABDOMINAL (TUMMY) WALL**

**COPYRIGHT TREHAN**



ANTERIOR ABDOMINAL(TUMMY) WALL

BOTH ROUND LIGAMENTS FIXED WITH  
ABDOMINAL WALL

UTERUS

LT OVARY &  
FALLOPIAN TUBE

RT OVARY &  
FALLOPIAN TUBE

**THIS PHOTOGRAPH DEMONSTRATES COMPLETION OF KEYHOLE OPERATION (VENTROSUSPENSION). BOTH LEFT AND RIGHT ROUND LIGAMENTS HAVE BEEN STITCHED WITH THE ANTERIOR ABDOMINAL (TUMMY) WALL BRINGING THE WOMB FORWARD AWAY FROM THE SPINE TOWARDS THE ABDOMINAL (TUMMY) WALL.**

**COPYRIGHT TREHAN**