

## Laparoscopic (Keyhole) Management of ovarian cyst in second trimester (after 12 weeks) of pregnancy



Mr A K Trehan FRCOG FRCS Edin  
Consultant Minimal Access Gynaecologist and Obstetrician  
Dewsbury & District Hospital

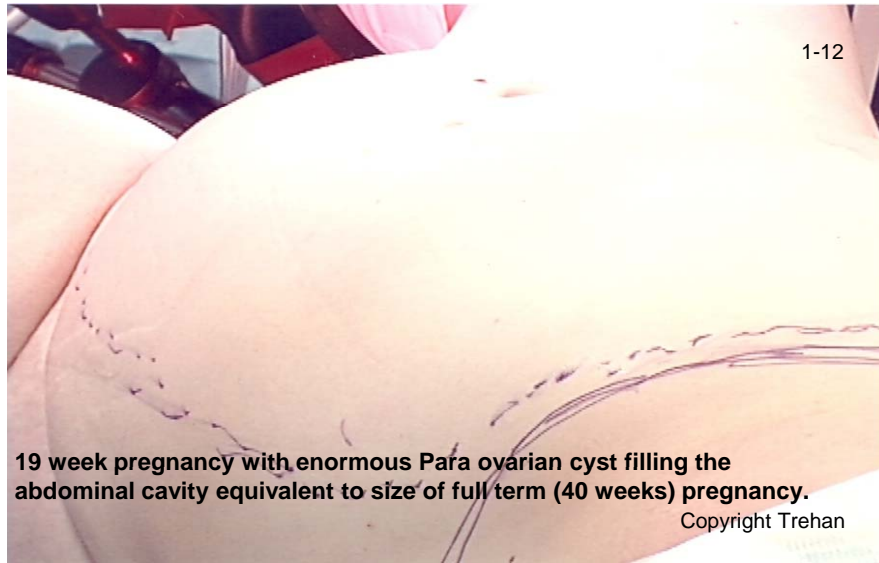
# Ovarian cysts in pregnancy

- Incidence of ovarian cyst in pregnancy is 1 in 1300 pregnancies with risk of cancerous cyst to be 1 in 15000 -- 32000 pregnancies.
- Cyst > 6cm at 16 weeks persist or increase (39%) and therefore risk of complications.
- Risks of ovarian cysts in pregnancy are: torsion (where the cyst twists around its blood supply resulting in death of the ovary), infection, rupture, haemorrhage, Obstruction of labour (17—21%), undiagnosed malignancy. Emergency surgery carries higher risk for baby.
- The management options are: conservative (do nothing, but as stated the risks as above), aspiration of the cyst (cyst is drained under ultrasound guide), ovarian cystectomy (cyst is removed via keyhole or open cut of the abdomen).
- Disadvantages of aspiration of the cyst are: recurrence of the cyst in 30—50%, fluid from aspiration cannot be used for diagnosis moreover there is risk of spillage of cyst contents which may cause spread of ovarian cancer if it is a cancerous cyst.
- Traditionally cysts are removed by open cut of the abdomen however it should be removed by keyhole means in view of several advantages of keyhole surgery:
  - General advantages are less pain thus less need for analgesics which could be harmful to the baby, less risk of infection, rapid recovery, less risk of blood clotting and better cosmetic results
  - Specific advantages of keyhole surgery for ovarian cysts in pregnancy include reduced manipulation of the uterus during surgery and thus decreased uterine irritability and so less risk of miscarriage and pre-term labour, less risk of poor scar healing and related wound complications due to abdominal stretching because of ongoing pregnancy and growing size of the uterus. Operation by open cut on the abdomen can not be done by low bikini cut. It has to be done by up and down large cut. Not only up and down cut has more complications as compared to bikini cut but it also produces a very ugly scar due to over stretching of the wound due to growing baby.

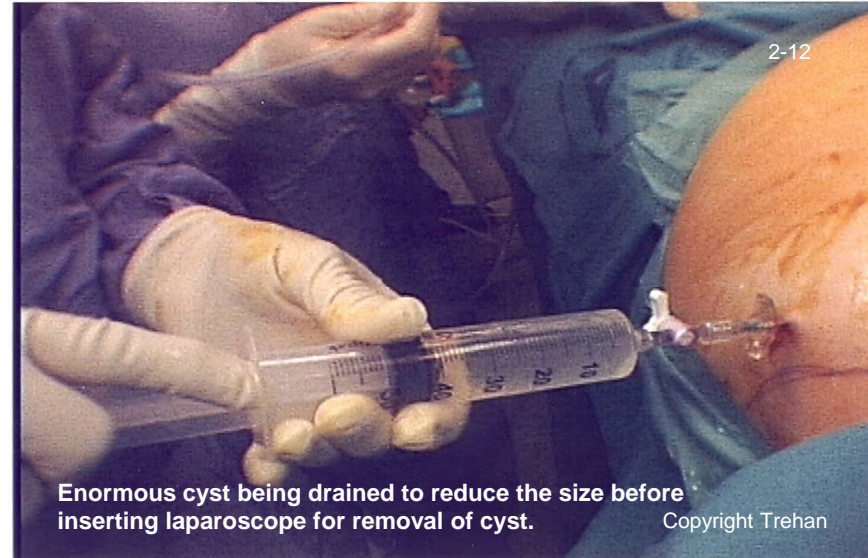
# Case of mid trimester pregnancy (19 weeks) with enormous Para Ovarian Cyst which is being removed by keyhole means.

The following slides 1-12 belongs to the same patient

(This case proves the fact that every non-cancerous cyst can be treated by keyhole means without having to cut open the abdomen)



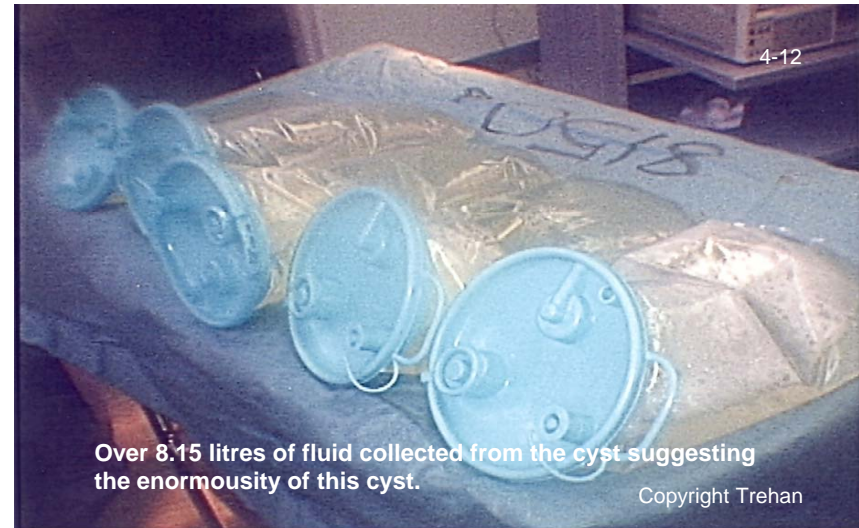19 week pregnancy with enormous Para ovarian cyst filling the abdominal cavity equivalent to size of full term (40 weeks) pregnancy.  
Copyright Trehan



Enormous cyst being drained to reduce the size before inserting laparoscope for removal of cyst.  
Copyright Trehan

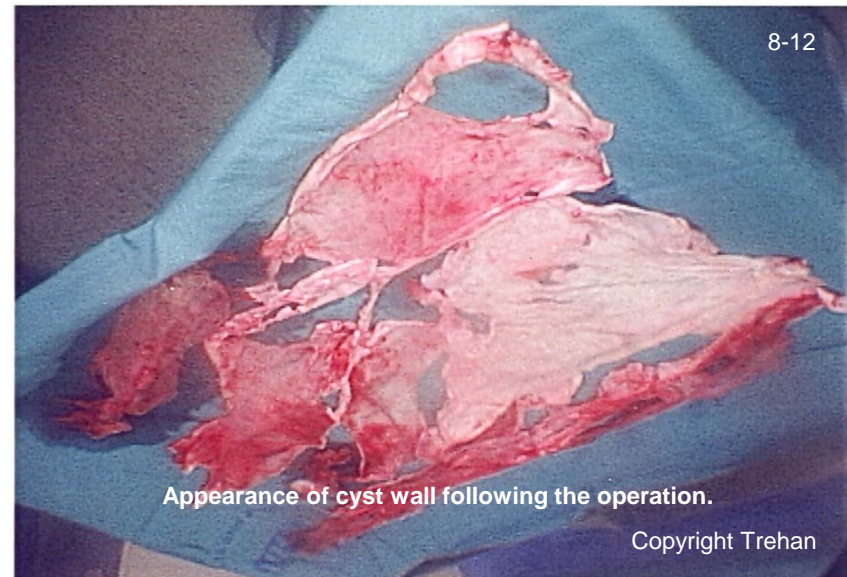
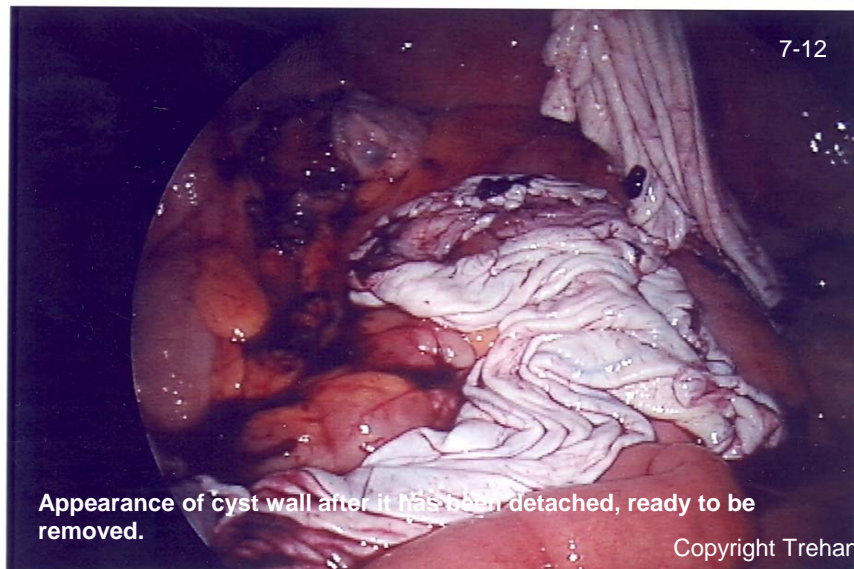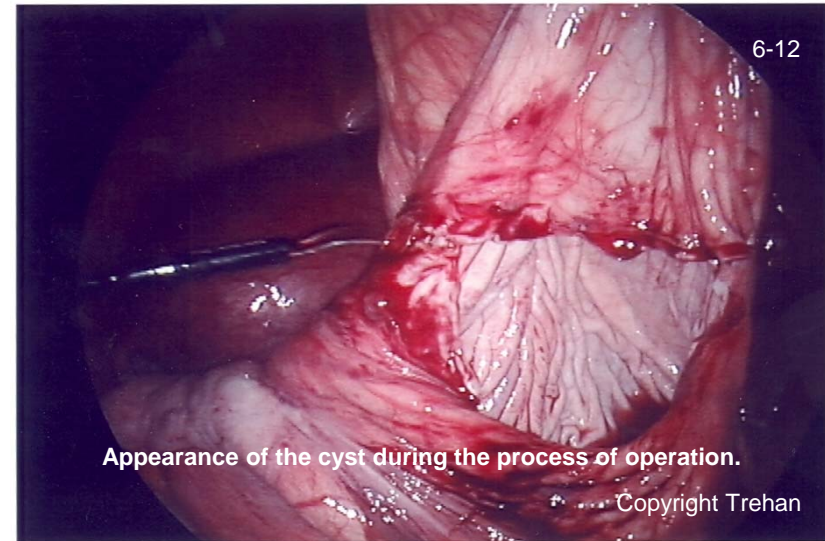
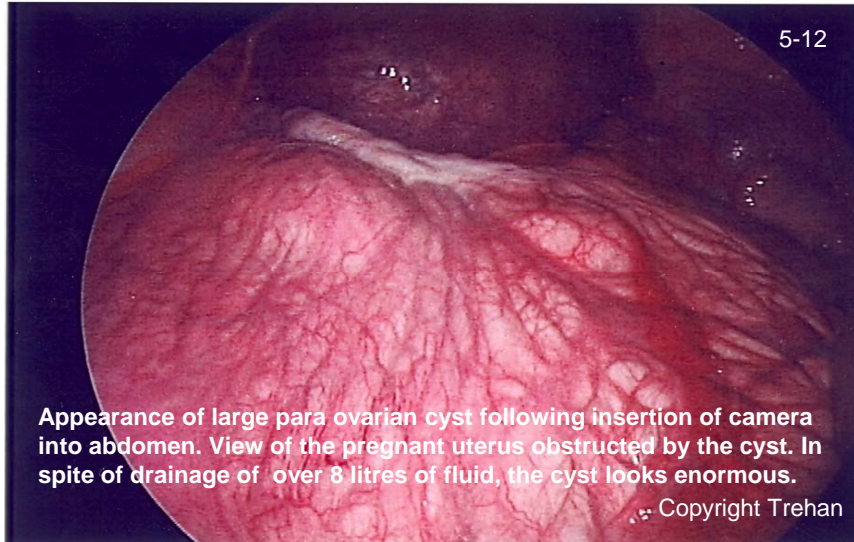


Drained cyst fluid being collected in bottles.  
Copyright Trehan

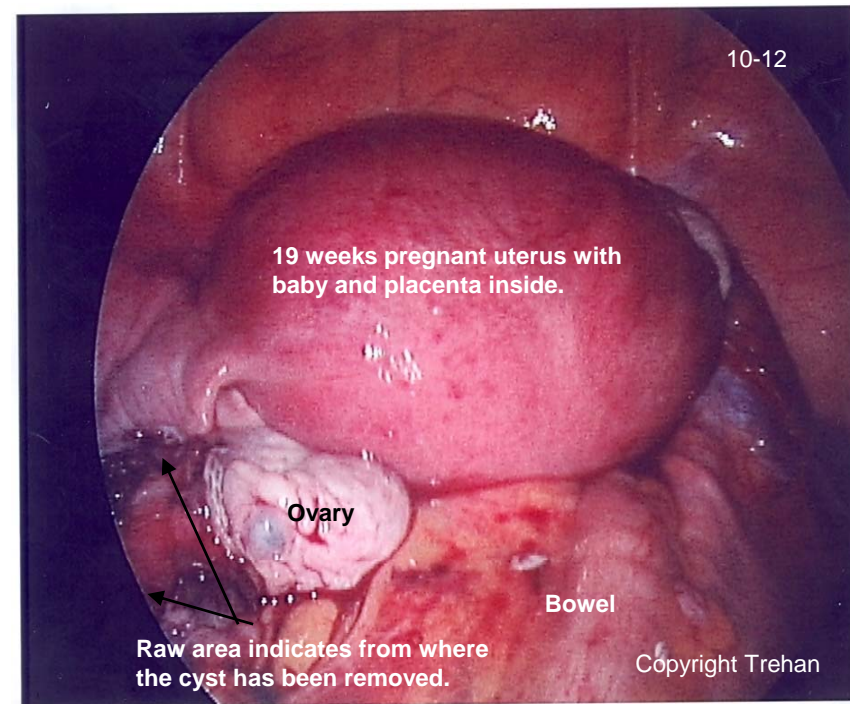
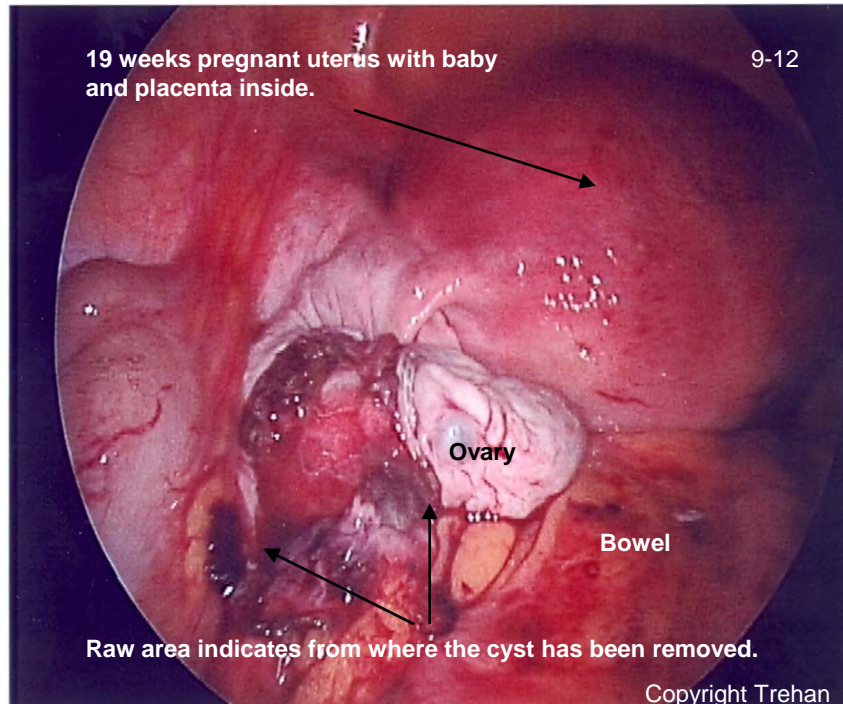


Over 8.15 litres of fluid collected from the cyst suggesting the enormosity of this cyst.  
Copyright Trehan

## Pictures during the process of operation

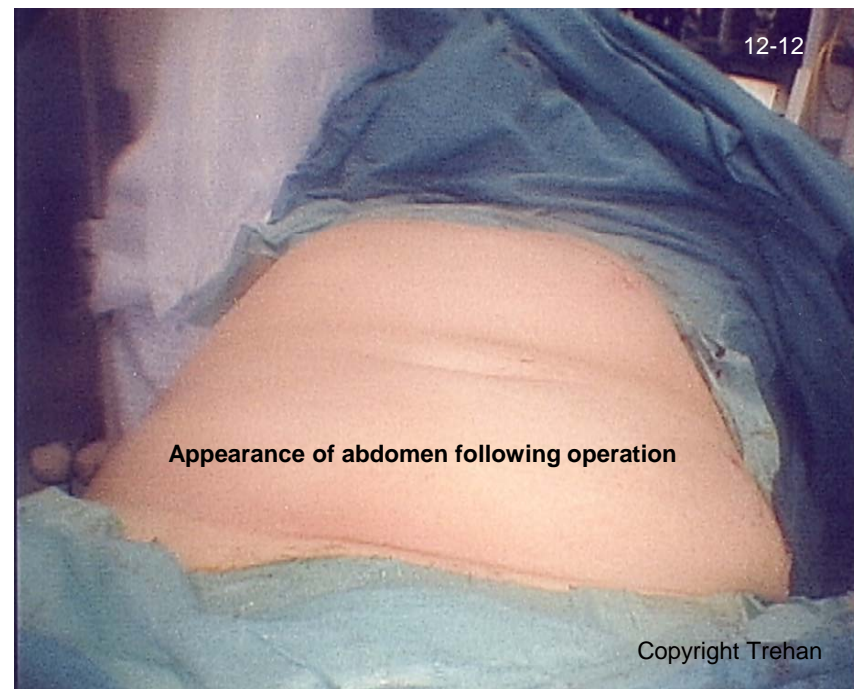
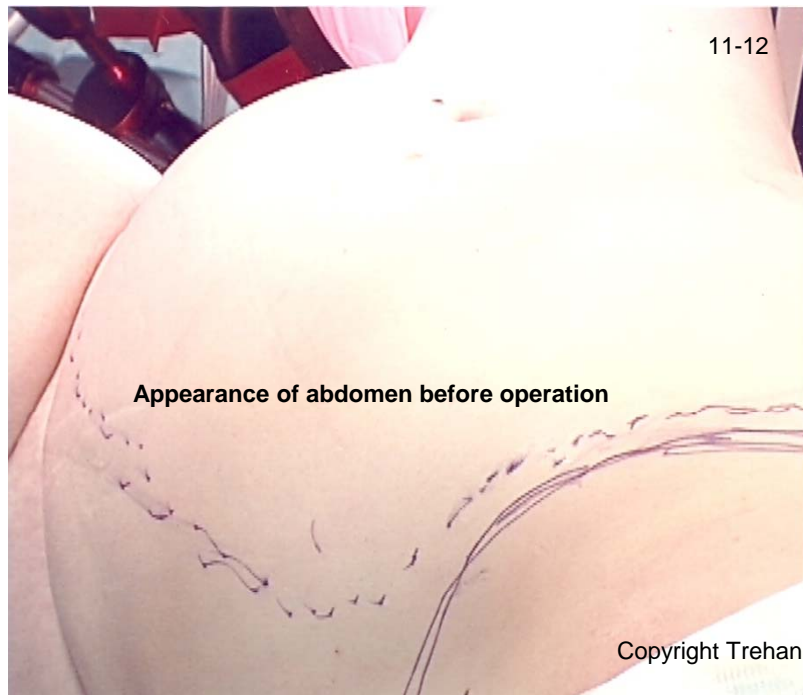
## Final pictures inside the abdomen after removal of large cyst



## **Pictures of abdomen comparing before and after the operation**

**(This patient was discharged only after one day stay in the hospital and delivered a healthy baby)**



For more information, visit:

<http://www.keyholehysterectomy.co.uk/>

<http://www.endometriosis-consultant.co.uk/>